VHG
British Viral Hepatitis Group

BHIVA Hepatology Highlights for the Healthcare Specialist

in collaboration with the British Viral Hepatitis Group

15 November 2017 • QEII Centre, London

Meeting sponsors

abbvie GILEAD MSD

BHIVA
British HIV Association

#BHIVA2017 www.bhiva.org

BHIVA
British HIV Association

BVHG
British Viral Hepatitis Group

Dr Douglas Macdonald

Royal Free Hospital, London

Speaker Name	Statement
Dr Douglas Macdonald	
Date : November	November 2017

BHIVA Hepatology Highlights for the Healthcare Specialist

in collaboration with the British Viral Hepatitis Group

15 November 2017 • QEII Centre, London

Does treating hepatitis lead to reversal of liver fibrosis?

Dr Doug Macdonald

BHIVA 2017

Jack

- 53yr old
- HIV/HCV coinfected
- ART for 13 years since diagnosis. Normal CD4 count, HIV undetected
- HCV Genotype 1b
- No alcohol history
- Fibroscan 22kPa,
- Liver US: “Irregular contour, no focal lesions”

ALT	AST	ALP	GGT	BILI	ALB	INR	PLT
190	130	121	66	22	35	1.2	110

Jack

- OGD (Baveno criteria):Grade II varices, no red signs, commenced on carvedilol
- HCV treated with DAAs, achieves SVR
- Continues US surveillance for HCC
- “Curiosity scan” at 18 months post-treatment: 10.5 kPa

Jack

You: Can I stop HCC surveillance? If not now, when?

Jack: Can I stop the carvedilol? If not now, when?

Fibrosis: learned helplessness

Conserved across **organs** – kidney, lung, liver, skin, gut etc

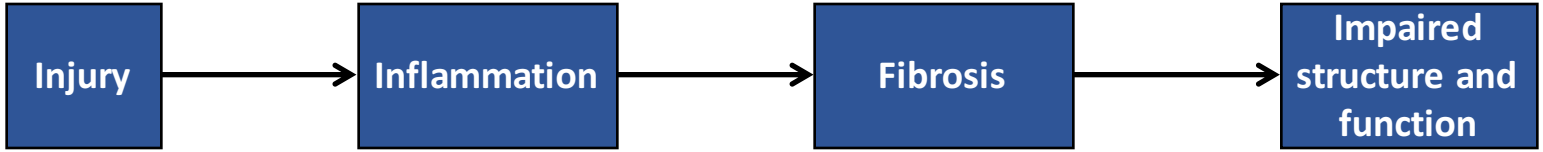

Highly conserved across **species**

Fibrosis and learned helplessness

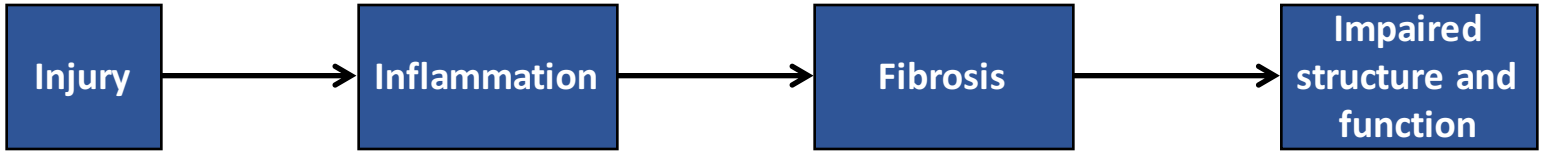

Antagonistic Pleiotropy?

Bridging Fibrosis

Liver Fibrosis

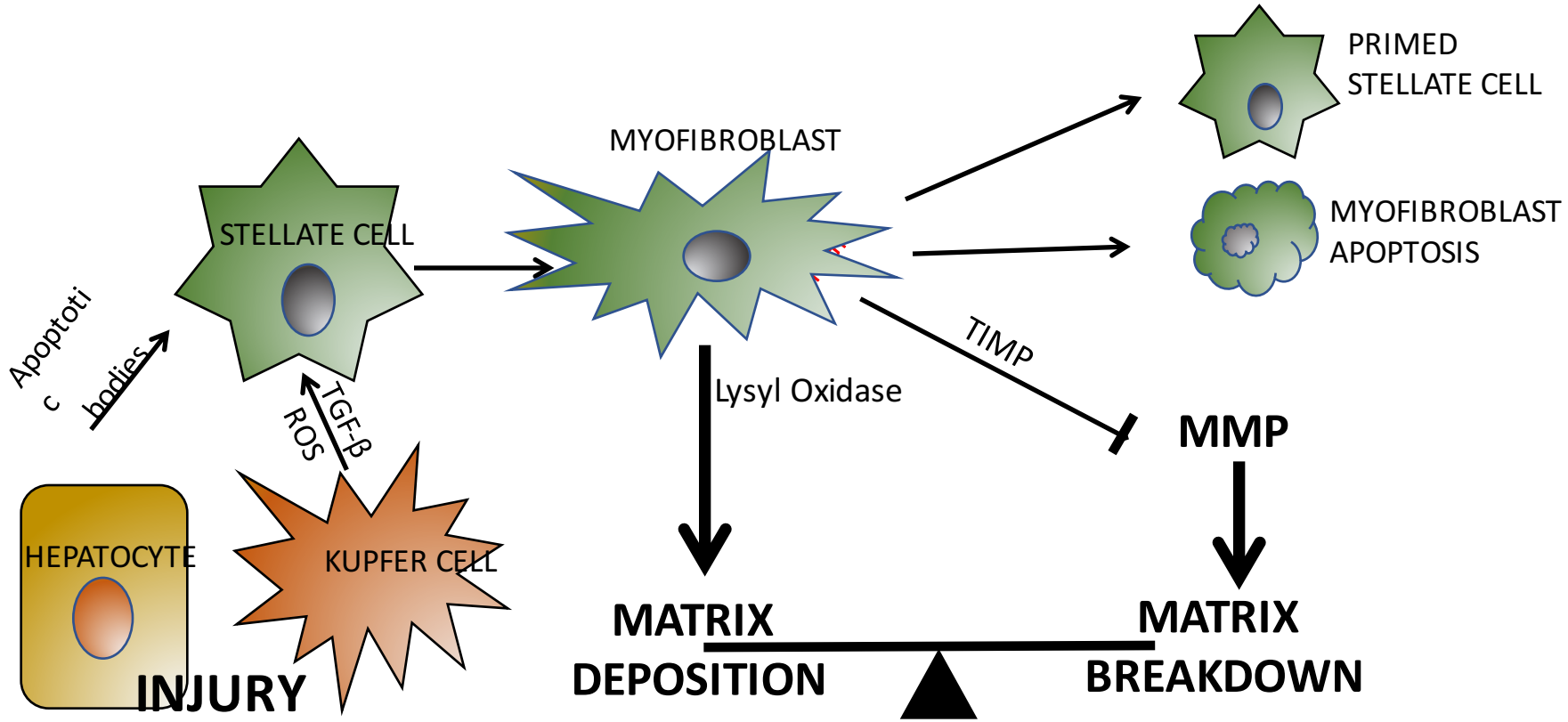

THE LANCET
Volume 381, Issue 9865, 9–15 February 2013, Pages 468-475

Hepatitis B: Marcellin et al

- 240 week prospective study of 348 patients on **TDF therapy for hepatitis B** with paired biopsy at beginning and end
- 74% of patients with cirrhosis (Ishak 5 or 6) at the beginning no longer had cirrhosis at the end

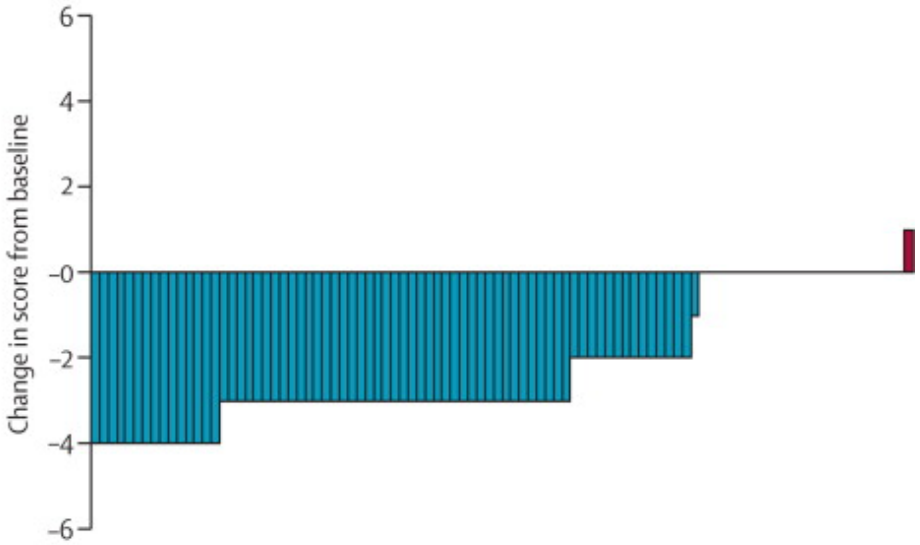

Gastroenterology
Volume 126, Issue 7, June 2004, Pages 1740-1749

Hepatitis D: Farci et al

- 36 patients treated with 48 weeks IFNα (high or low dose) followed prosepectively for a mean of 12 years with paired biopsy pre-treatment and post-treatment
- Significant improvement in Fibrosis stage in biochemical and HDV RNA responders

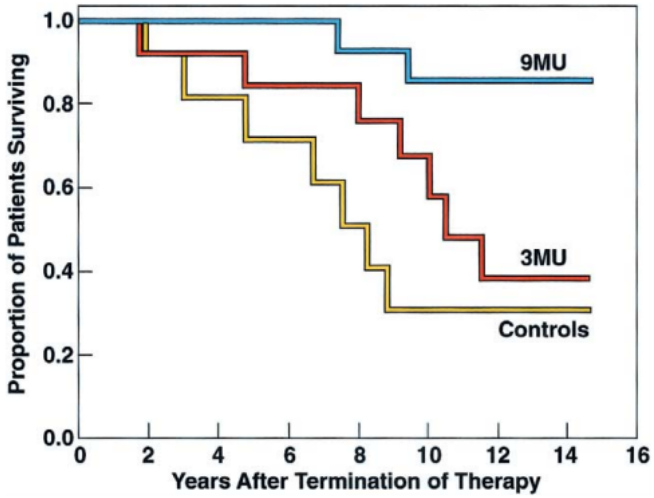

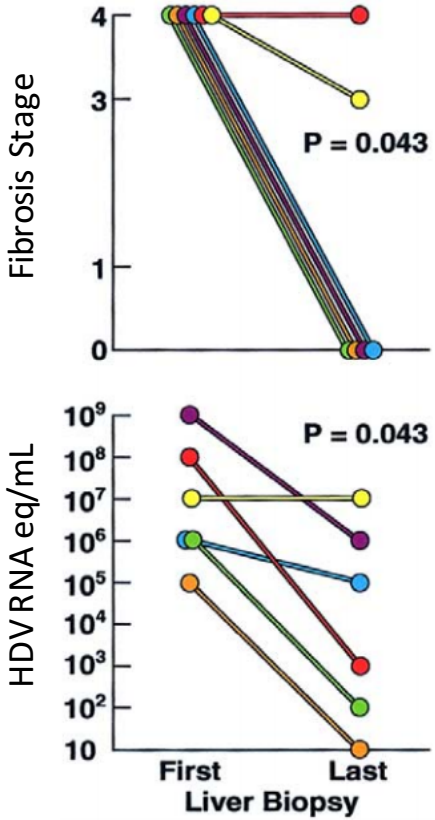

Hepatitis C: Shiffman et al

Annals of Hepatology
July-August, Vol. 13 No. 4, 2014: 340-349

- 348 patients receiving either no treatment or a single course of IFN-based treatment followed for 5 years with paired liver biopsy
- 112 achieved SVR

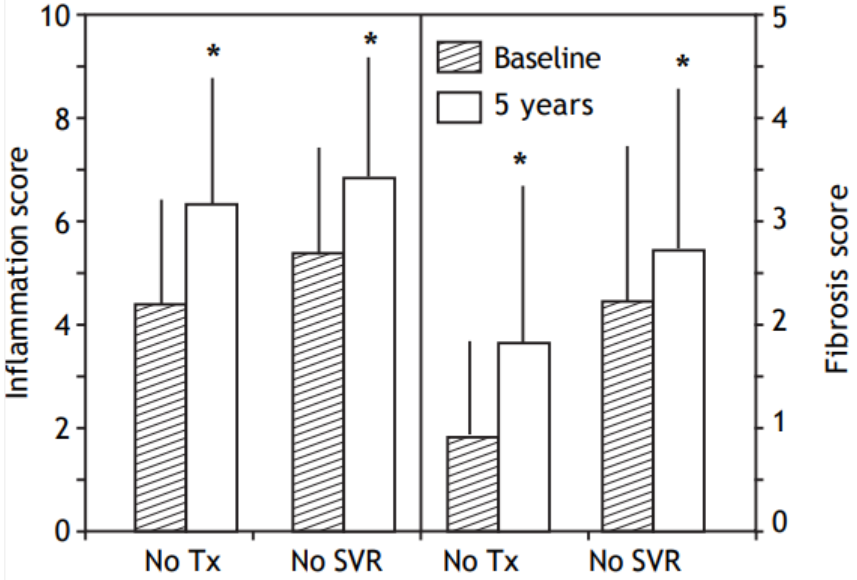

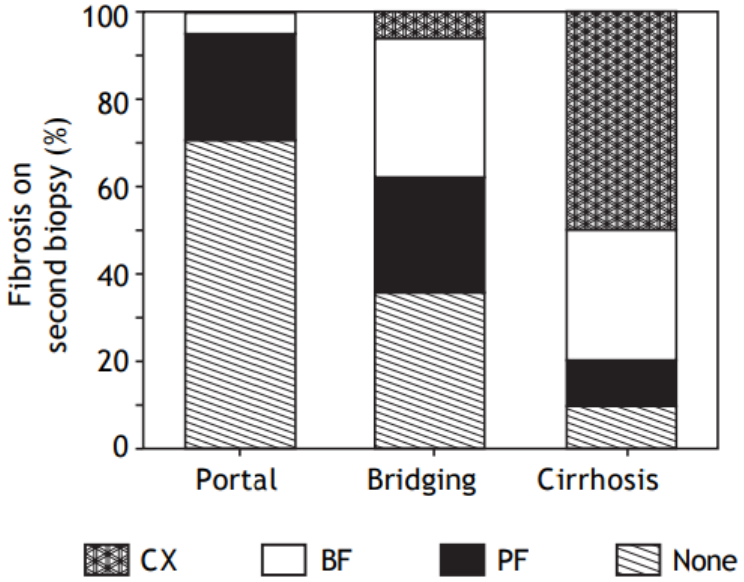

Hepatitis C: Shiffman et al

Annals of Hepatology
July-August, Vol. 13 No. 4, 2014: 340-349

- 348 patients receiving either no treatment or a single course of IFN-based treatment followed for 5 years with paired liver biopsy
- 112 achieved SVR

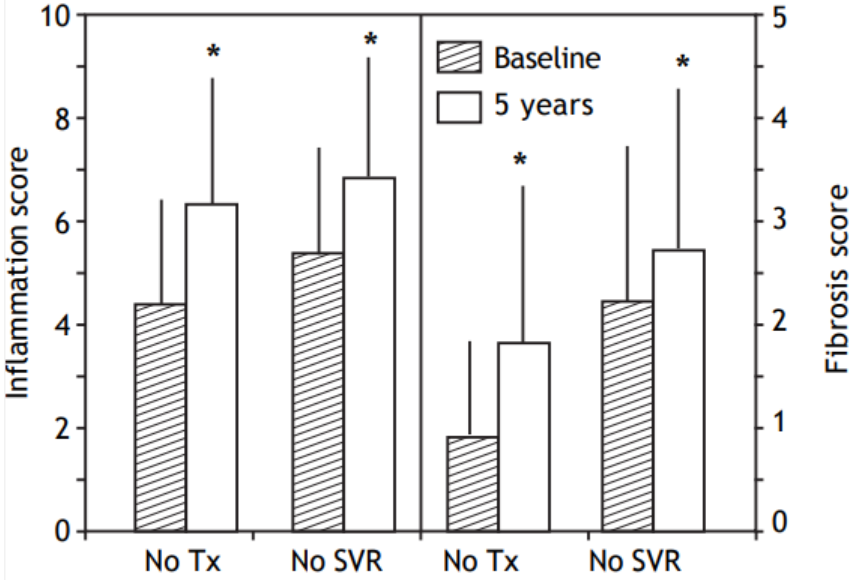

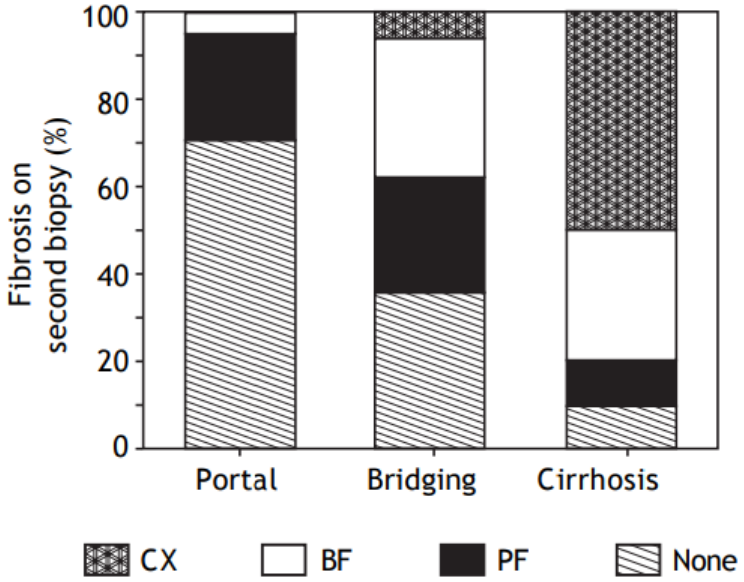

GASTROENTEROLOGY 1996;110:1107–1119

Haemochromatosis: Niederau et al

- 251 patients with HH followed for ~14 years with paired biopsy in 185 before and after iron removal therapy

Fibrosis stage	At diagnosis (%)	After documentation of iron removal (%)	Improved	Worsened	Unchanged	Total
0	21/185 (11.4)	30/185 (16.2)	0	1	20	21
1	32/185 (17.3)	42/185 (22.7)	10	1	21	32
2	39/185 (21.8)	32/185 (17.3)	20	0	19	39
3	93/185 (50.2)	81/185 (43.8)	12	0	81	93
Total			42	2	141	185

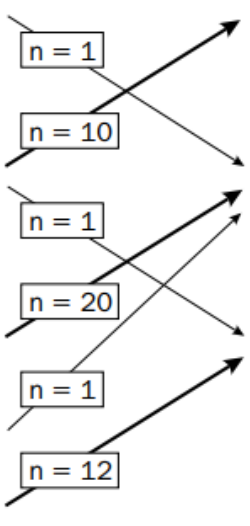

NOTE. $\chi^2 = 33.19$; $P = 0.000009625$.

Autoimmune hepatitis: Czaja et al

Journal of Hepatology
Volume 40, Issue 4, April 2004, Pages 646-652

- 87 patients with AIH treated with corticosteroids and biospied pre- and 63 months post- treatment

Histological findings	Initial tissue specimens (*N*=87)	Last tissue specimens (*N*=87)	Follow-up interval (mo)
Fibrosis score	3.4±0.2**	2.6±0.2**	63±6
HAI	6.8±0.5*	2.1±0.2*	63±6
Cirrhosis	14 (16)	11 (13)	63±6

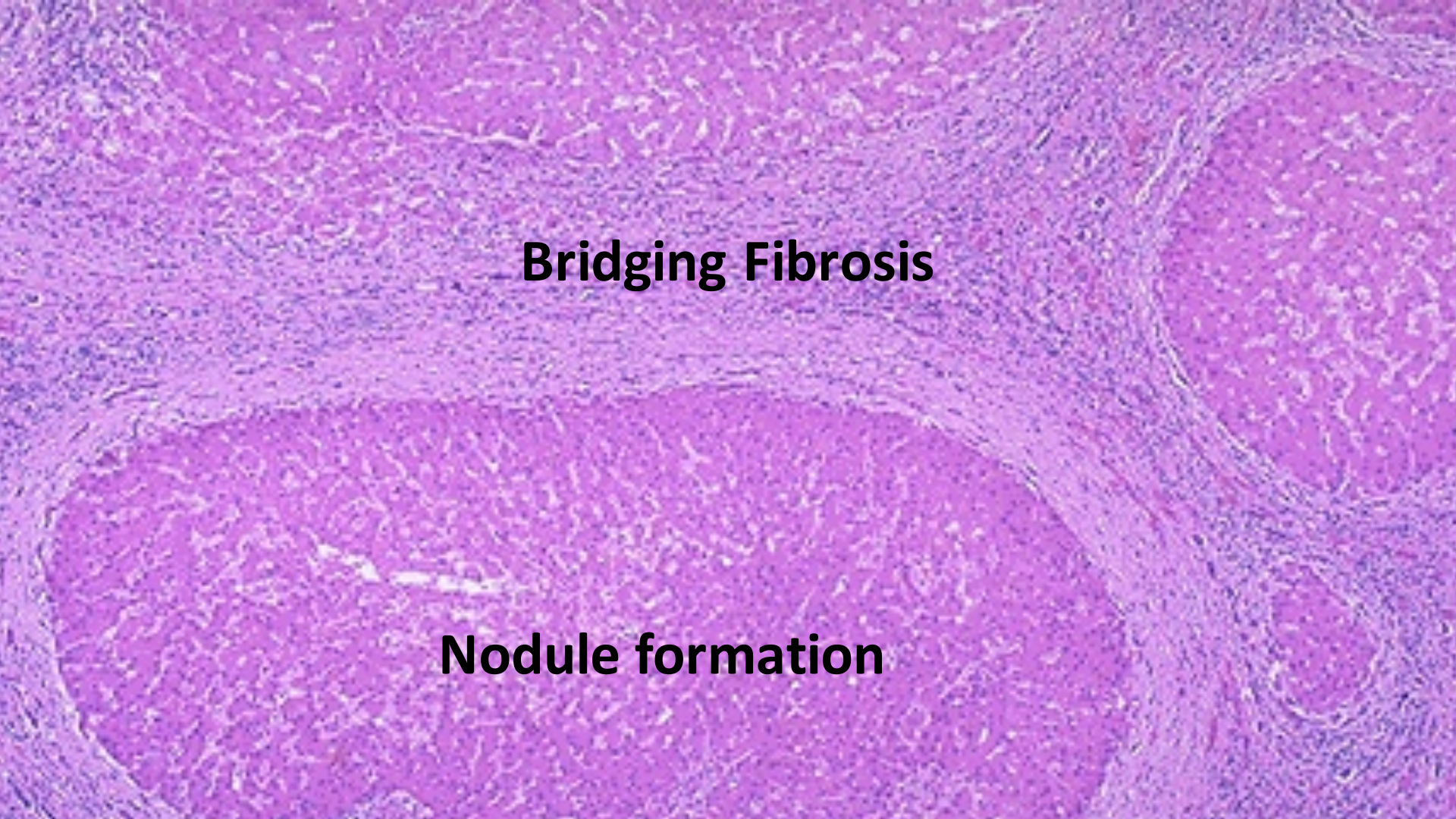
Bridging Fibrosis
Nodule formation

Axolotl


EVERY DAY THIS EAGLE EATS MY LIVER...
...AND ALL BECAUSE ZEUS IS ANGRY WITH ME FOR GIVING FIRE TO MANKIND.
OH, WELL, MY SUFFERING IS WORTH IT—I'M SURE MANKIND HAS MADE GOOD USE OF MY GIFT!
MEANWHILE...
© Mark Weinstein

Higgins GM, Anderson RM. Experimental pathology of the liver. I. Restoration of the liver following partial surgical removal. Arch Pathol Volume 272, 186-202

- Partial hepatectomy model of liver regeneration in rats
- 60-70% of the liver removed

- Liver achieves original mass after 14 days

Brues AM, Marble BB. AN ANALYSIS OF MITOSIS IN LIVER RESTORATION. J Exp Med. 1937 Jan 1;65(1):15-27

- Partial hepatectomy model of liver regeneration in rats
- Counted proportion of mitotic hepatocytes in regenerating liver

Brues AM, Marble BB. AN ANALYSIS OF MITOSIS IN LIVER RESTORATION. J Exp Med. 1937 Jan 1;65(1):15-27

Whether or not this explains cell multiplication as well as tissue hypertrophy, we may consider as a first approximation for purposes of a mathematical expression, that the rate of cell increase begins maximally and then is constantly retarded so that it remains proportional to the num ng the original

"Hepatostat"

Time postoperative, *days*.	4	6
Actual No., *per cent*. .	72.0	81.0
Calculated No., *per ce*	74.8	87.8

cell number as a limit. This type of growth is commonly seen by the embryologist, and would have the general formula:

$$N = C(1 - e^{-kt}) \quad (1)$$

Liver Regeneration

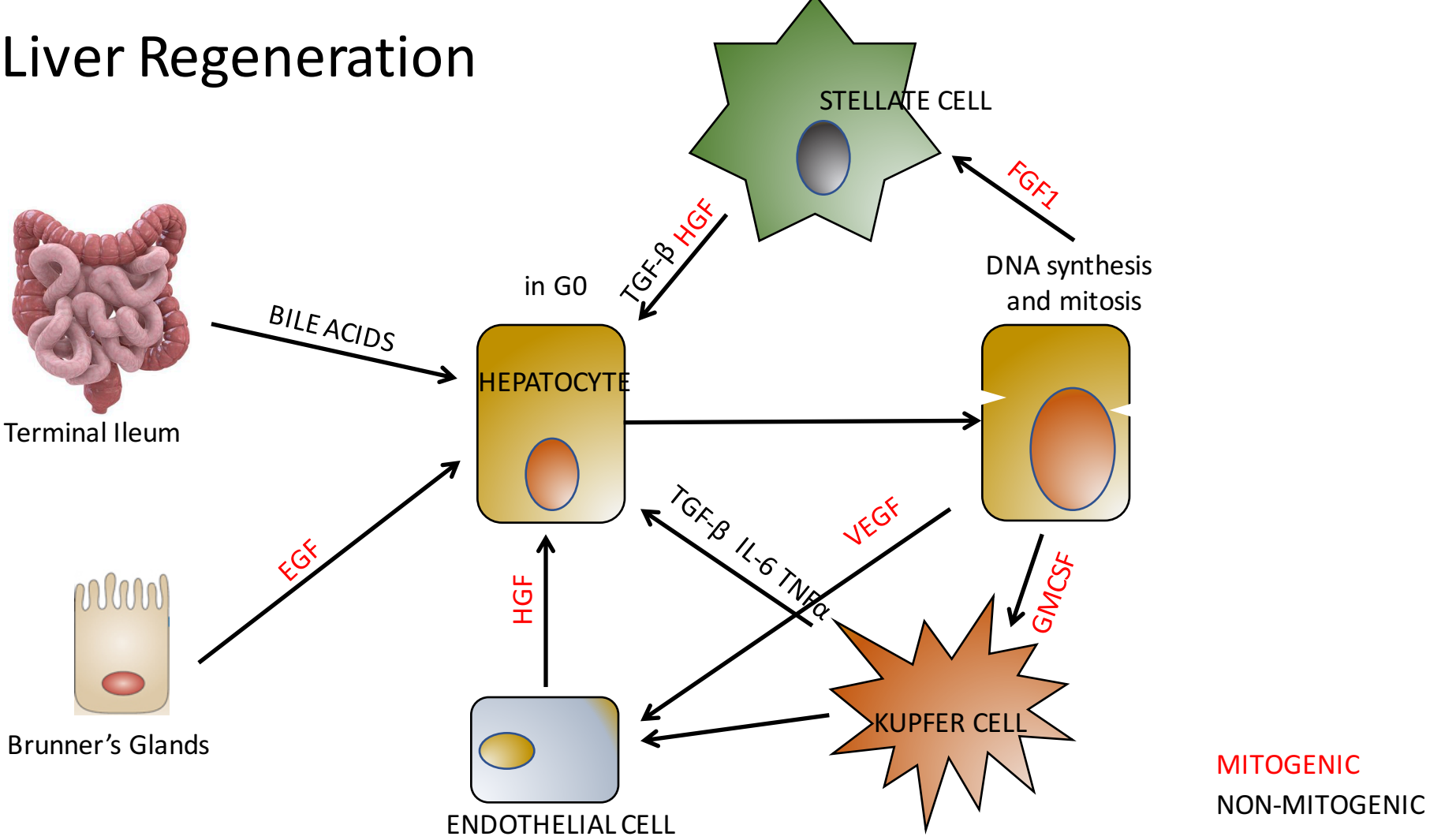

Termination

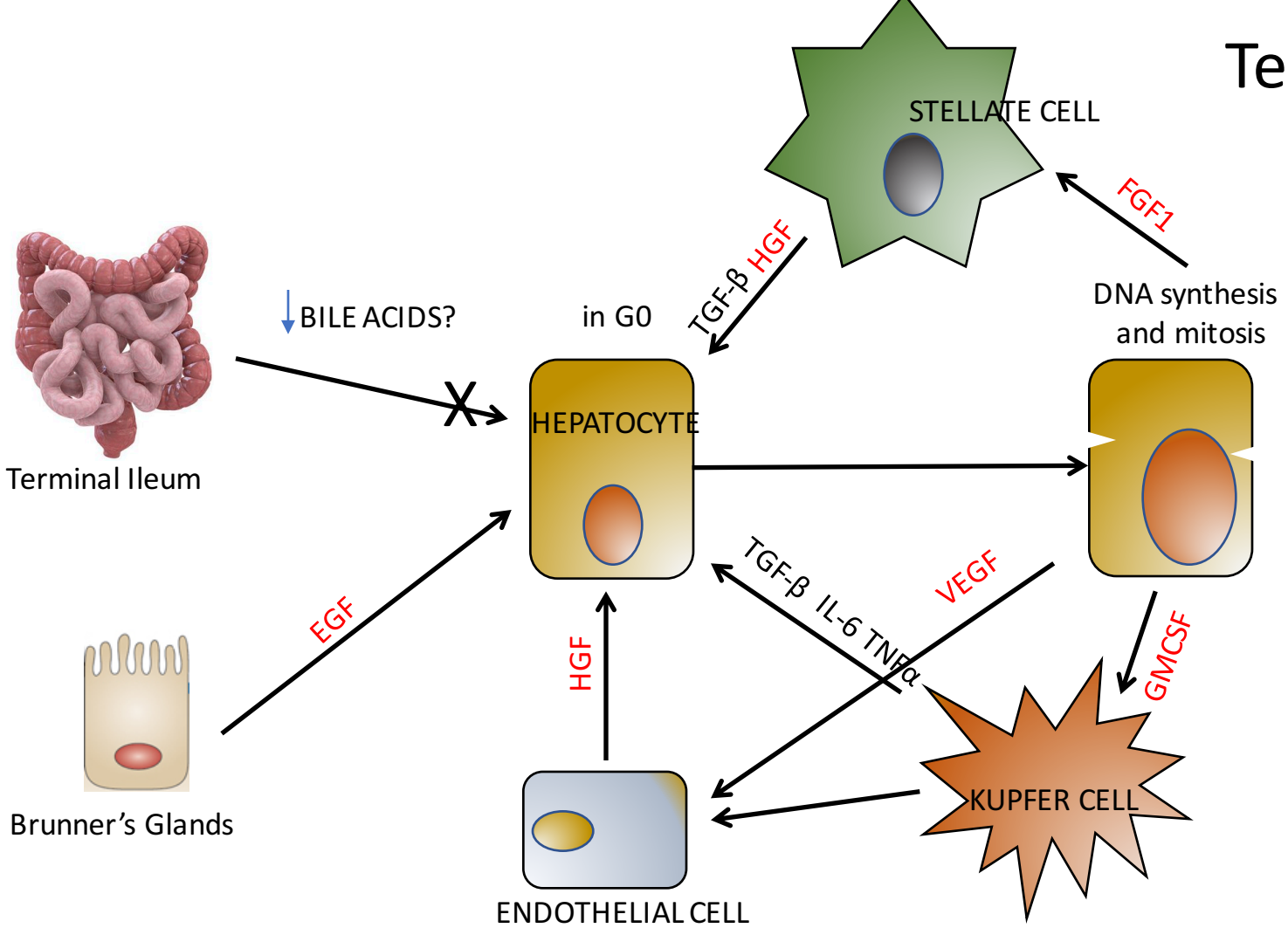

MITOGENIC

NON-MITOGENIC

The Dark Side of Liver Regeneration

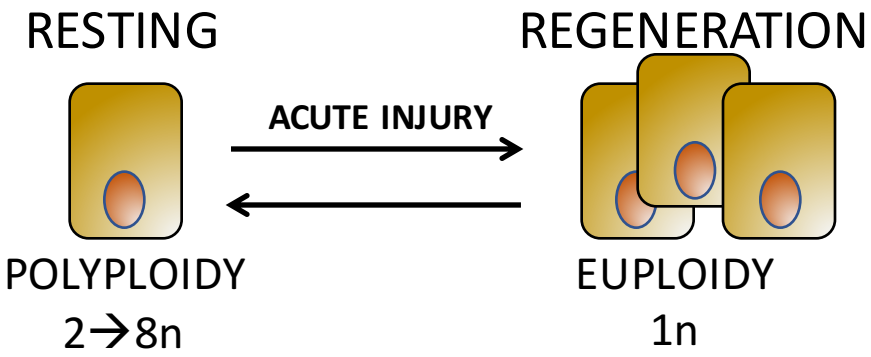

The Dark Side of Liver Regeneration

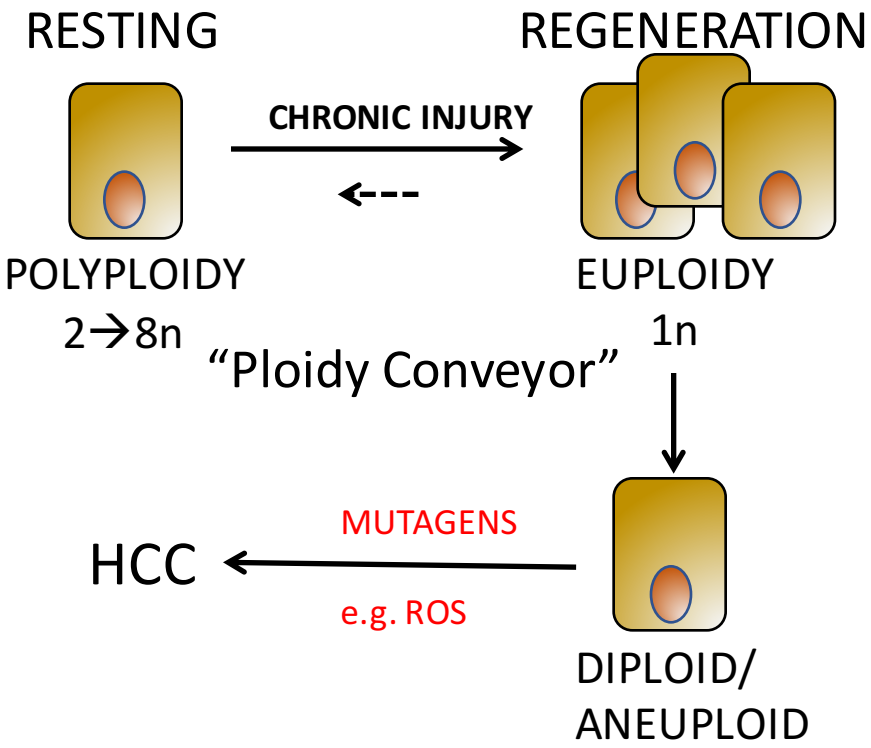

Jack

You: Can I stop HCC surveillance? If not now, when?

Jack: Can I stop the carvedilol? If not now, when?

Hepatitis B: Marcellin et al

THE LANCET
Volume 381, Issue 9865, 9–15 February 2013, Pages 468-475

- 240 week prospective study of 348 patients on **TDF therapy for hepatitis B** with paired biopsy at beginning and end
- 74% of patients with cirrhosis (Ishak 5 or 6) at the beginning no longer had cirrhosis at the end

- ***11 patients developed HCC, most after year 1 and none had paired biopsies***

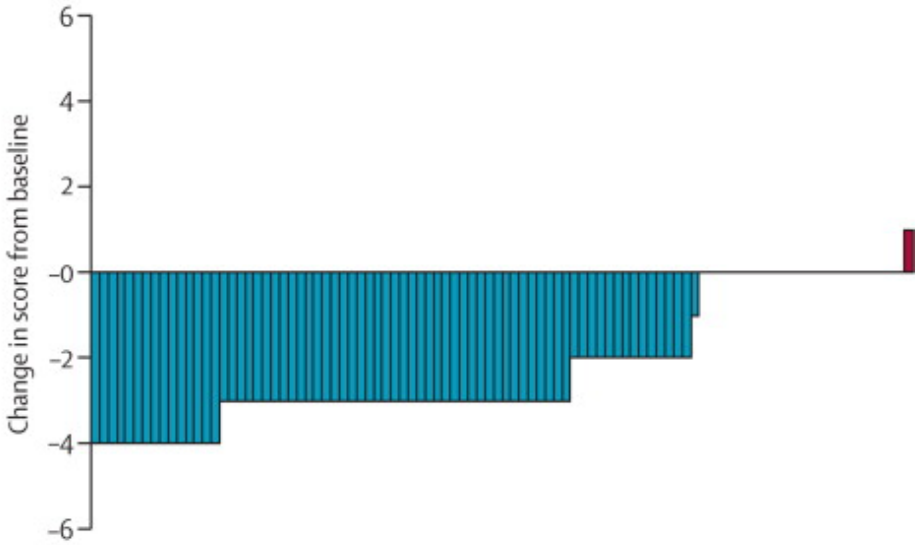

Gastroenterology
Volume 126, Issue 7, June 2004, Pages 1740-1749

Hepatitis D: Farci et al

- 36 patients treated with 48 weeks IFNα (high or low dose) followed prosepectively for a mean of 12 years with paired biopsy pre-treatment and post-treatment

- Significant improvement in Fibrosis stage in biochemical and HDV RNA responders

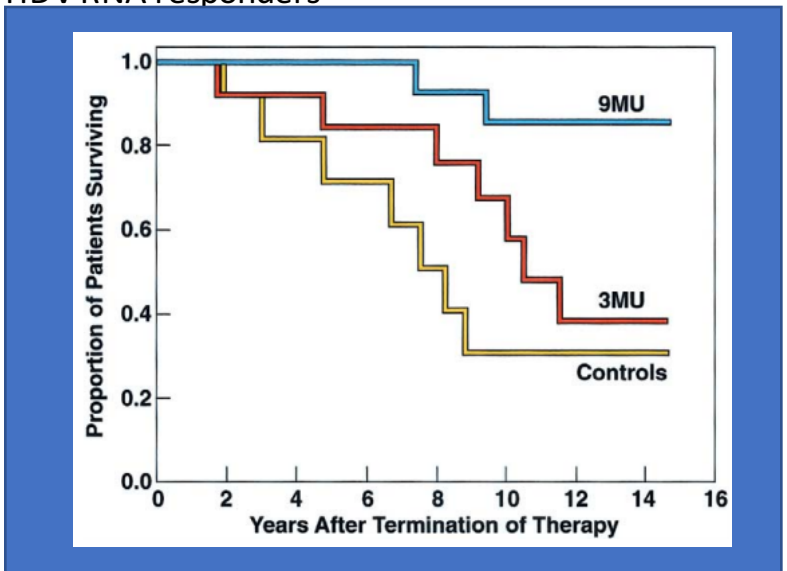

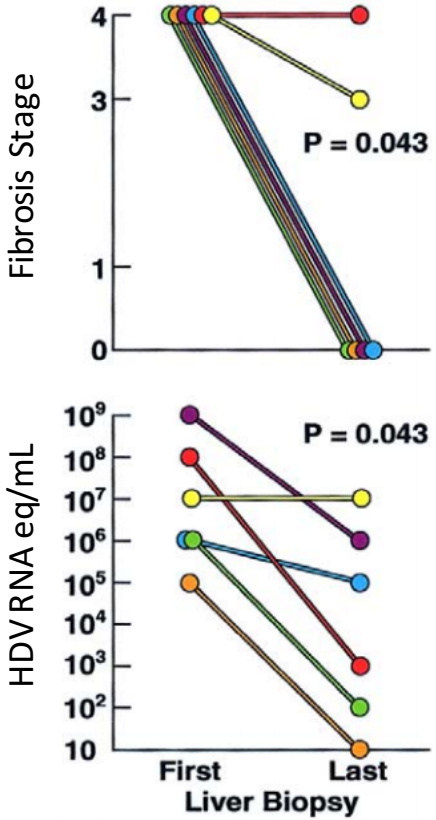

Hepatitis C: Shiffman et al

Annals of Hepatology
July-August, Vol. 13 No. 4, 2014: 340-349

- 348 patients receiving either no treatment or a single course of IFN-based treatment followed for 5 years with paired liver b

- 112 achieved SVR

No liver-related clinical outcomes reported

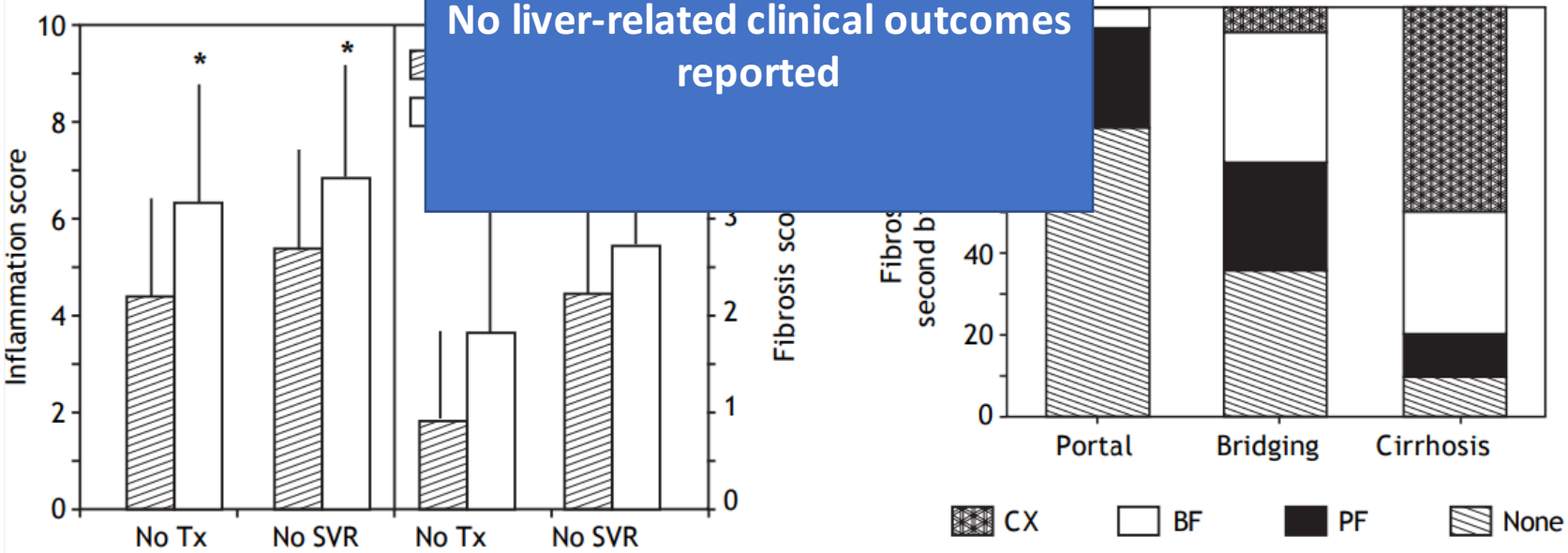

GASTROENTEROLOGY 1996;110:1107–1119

Haemochromatosis: Niederau et al

- 251 patients with HH followed for ~14 years with paired biopsy in 185 before and after iron removal therapy

Fibrosis stage	At diagnosis (%)			Worsened	Unchanged	Total
0	21/185 (11.4)			1	20	21
1	32/185 (17.3)			1	21	32
2	39/185 (21.8)	32/185 (17.3)	20	0	19	39
3	93/185 (50.2)	81/185 (43.8)	12	0	81	93
Total			42	2	141	185

NOTE. $\chi^2 = 33.19$; $P = 0.000009625$.

No analysis of clinical outcome in histological improvers versus non-improvers

Autoimmune hepatitis: Czaja et al

Journal of Hepatology
Volume 40, Issue 4, April 2004, Pages 646-652

- 87 patients with AIH treateed with corticosteroids and biospied pre- and 63 months post- treatment

No analysis of clinical outcome in histological improvers versus non-improvers

No significant change in the cirrhotic patients

Histological findings	Initia (*N*=87)	ns (*N*=87)	Follow-up interval (mo)
Fibrosis score	3.4±0.2**	2.6±0.2**	63±6
HAI	6.8±0.5*	2.1±0.2*	63±6
Cirrhosis	14 (16)	11 (13)	63±6

Gastroenterology. 2011 Mar;140(3):840-9;

HCC after HCV SVR: Lok et al (HALT-C)

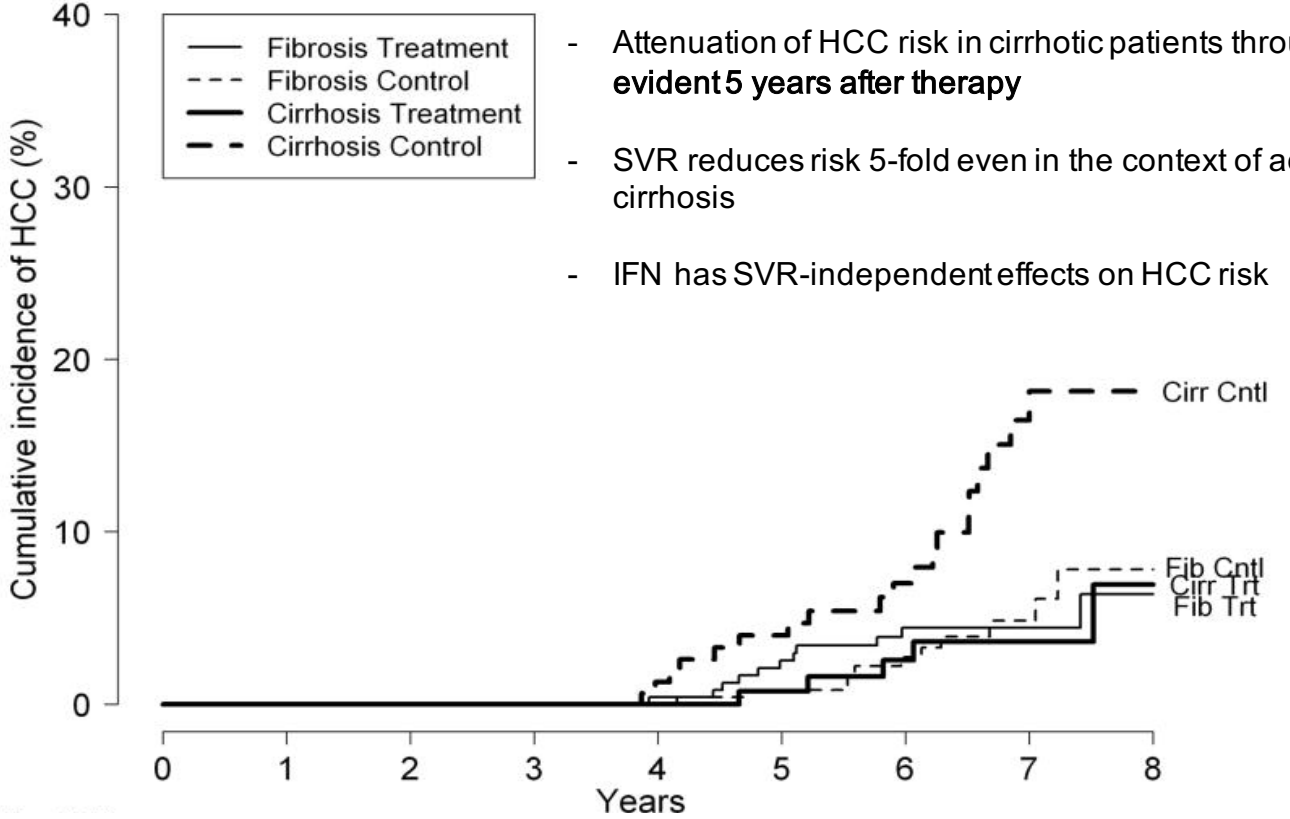

- Attenuation of HCC risk in cirrhotic patients through P-IFN treatment **only evident 5 years after therapy**
- SVR reduces risk 5-fold even in the context of advanced fibrosis and cirrhosis
- IFN has SVR-independent effects on HCC risk

Gastroenterology. 2017 Oct;153(4):996-1005;

HCC after HCV SVR: Kanwal et al

- Retrospective cohort study of 22,500 HCV patients treated with DAA in VHA clinics between 1st Jan 2015 and 31st Decemeber 2015
- 19,518 had SVR, 2982 non-SVR

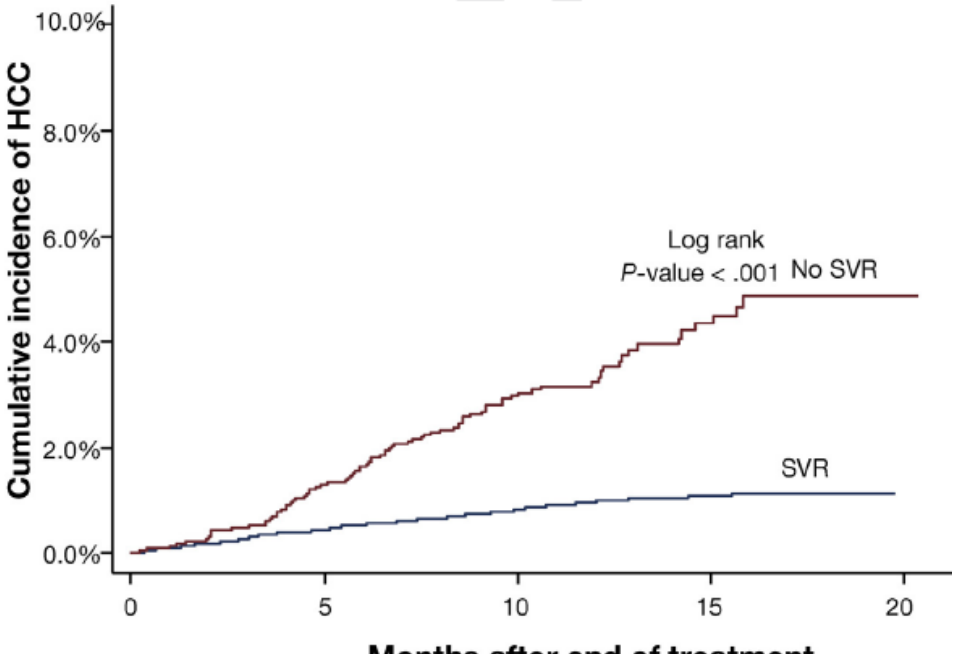

N at risk (N HCC)									
Achieved SVR	19518	(85)	19372	(68)	14364	(29)	6128	(1)	0
No SVR	2982	(35)	2453	(36)	1617	(14)	636	(3)	5

PHTN after HCV SVR: Mauro et al

HEPATOLOGY
2017 Sep 27. doi: 10.1002/hep.29557

- Paired biopsy study of 112 patients treated for recurrent HCV post-OLT (pre- and 12 months post-treatment)
- **Paired HVPG measurements, ELF and FIbroscan**

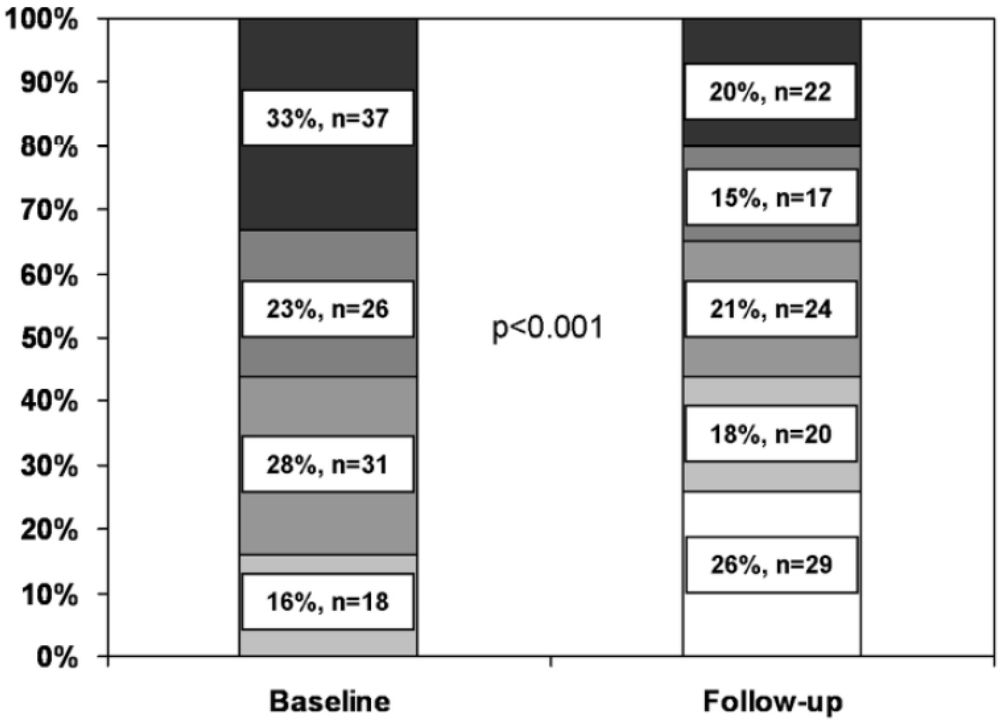

PHTN after HCV SVR: Mauro et al

HEPATOLOGY
2017 Sep 27. doi: 10.1002/hep.29557

- Mean HVPG reduction from 7.5 to 5
- **ELF and Fibroscan AUROC of 0.89 and 0.88 for detection of CSPH (HVPG >10mmHg) post HCV -treatment**

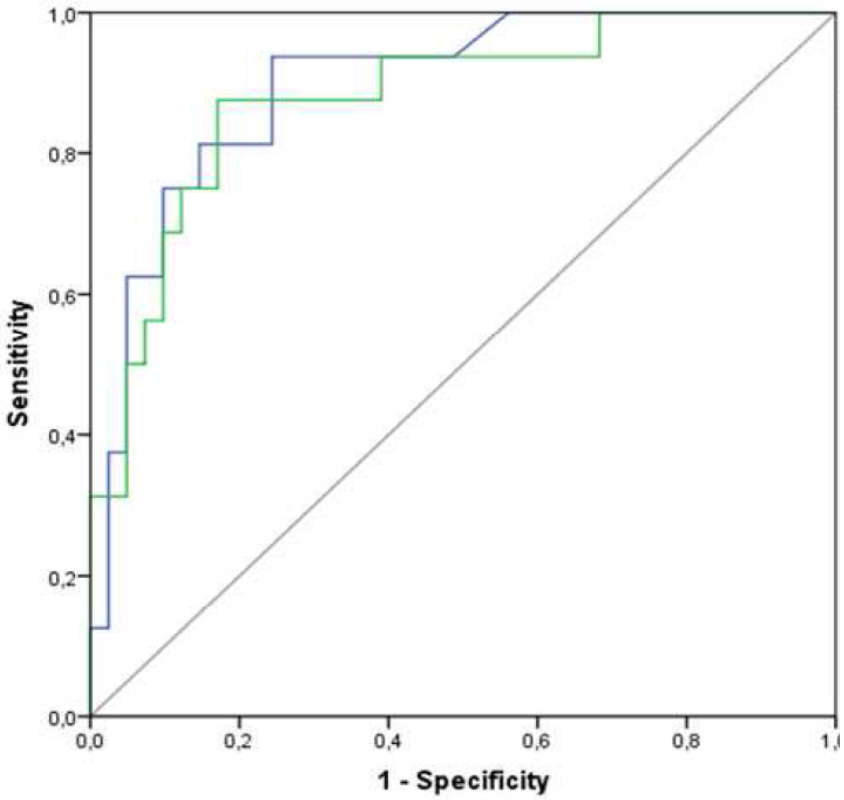

Jack

Does a fall in elastography score indicate reduced risk of HCC?

Or variceal bleeding?

Summary

- Cirrhosis is a composite of both fibrosis and nodular regeneration
- Fibrosis regresses with removal of a chronic injurious insult…
- …but measures of fibrosis may not represent
  - Diploid/Aneuploidy and HCC risk
  - Portal Hypertension and risk of bleeding

More prospective studies of post-DAA HCV treatment are needed that

1. Include clinically meaningful outcome measures paired with
2. non-invasive assessments in regular clinical use

Jack will remain under follow up for now….

Jack (supplementary)

Is his HIV status relevant?

HIV enteropathy

Normal CD4+ T-cell count

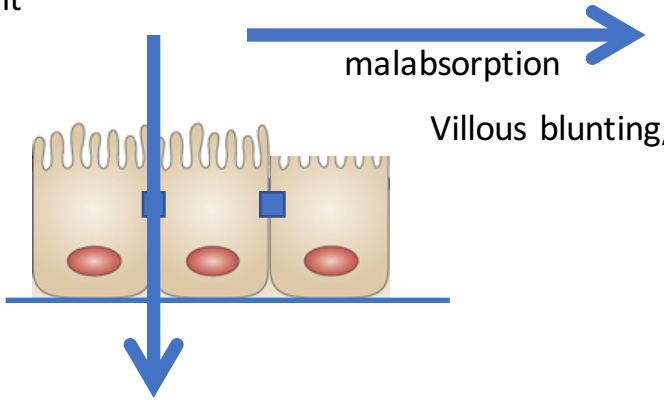

Batman, P.A. et al. HIV enteropathy: crypt stem and transit cell hyperproliferation induces villous atrophy in HIV/Microsporidia-infected jejunal mucosa. AIDS 21, 433–439 (2007)

HIV enteropathy

Direct virotoxic effect?

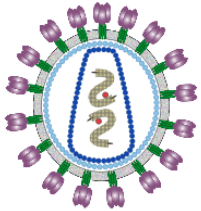

Tat → increases enterocyte Ca++
Gp120 → Stimulates enterocyte replication

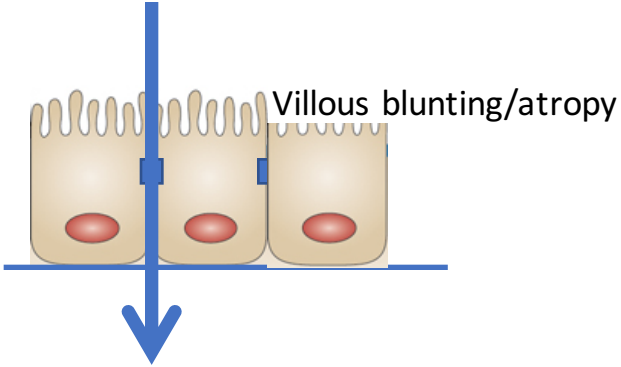

→ Increased permeability x 5

Batman, P.A., Fleming, S.C., Sedgwick, P.M., MacDonald, T.T. & Griffin, G.E. HIV infection of human fetal intestinal explant cultures induces epithelial cell proliferation. AIDS 8, 161–167 (1994)

Maresca, M. et al. The virotoxin model of HIV-1 enteropathy: involvement of GPR15/Bob and galactosylceramide in the cytopathic effects induced by HIV-1 gp120 in the HT-29-D4 intestinal cell line. J. Biomed. Sci. 10, 156–166 (2003)

HIV enteropathy

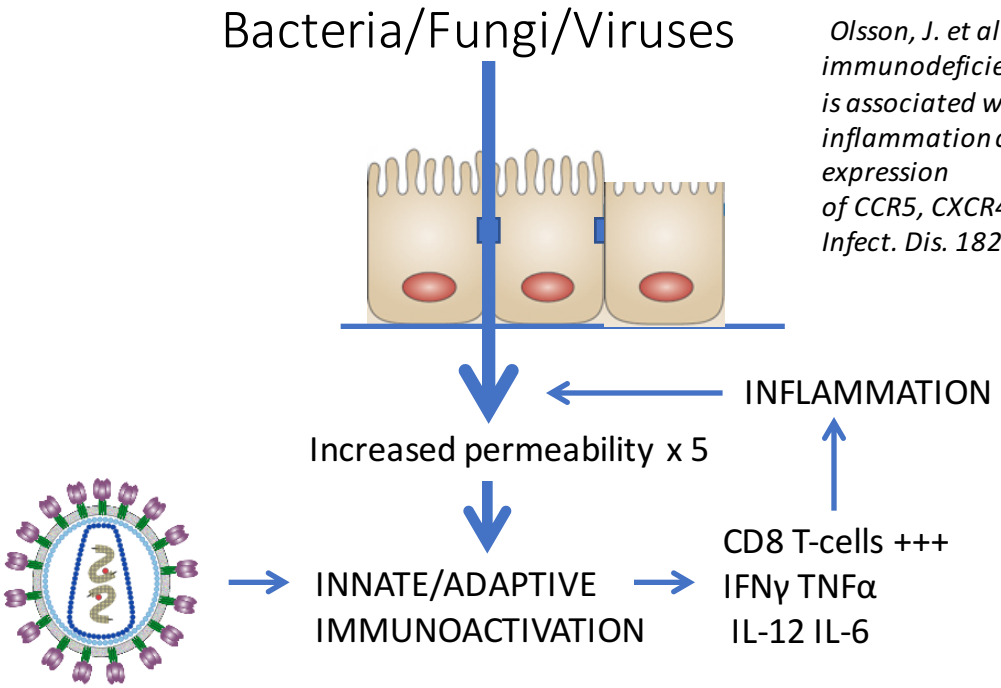

Olsson, J. et al. Human immunodeficiency virus type 1 infection is associated with significant mucosal inflammation characterized by increased expression of CCR5, CXCR4, and beta-chemokines. J. Infect. Dis. 182, 1625–1635 (2000)

HIV enteropathy

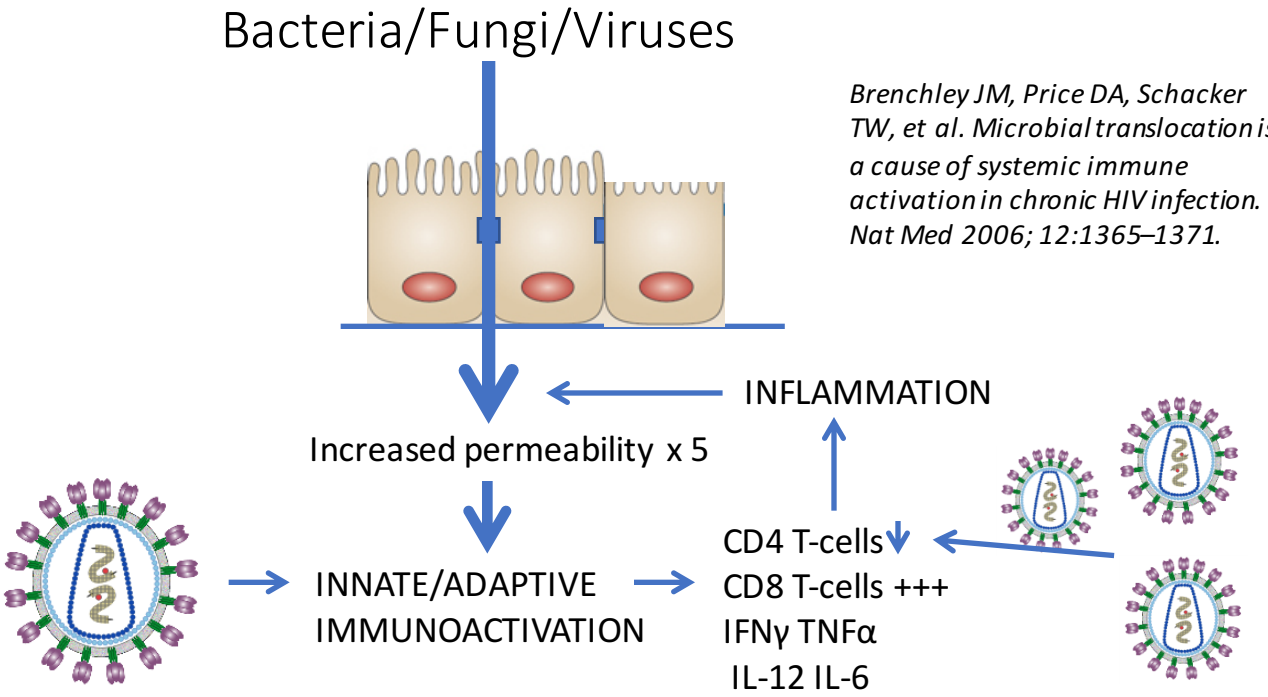

Brenchley JM, Price DA, Schacker TW, et al. Microbial translocation is a cause of systemic immune activation in chronic HIV infection. Nat Med 2006; 12:1365–1371.

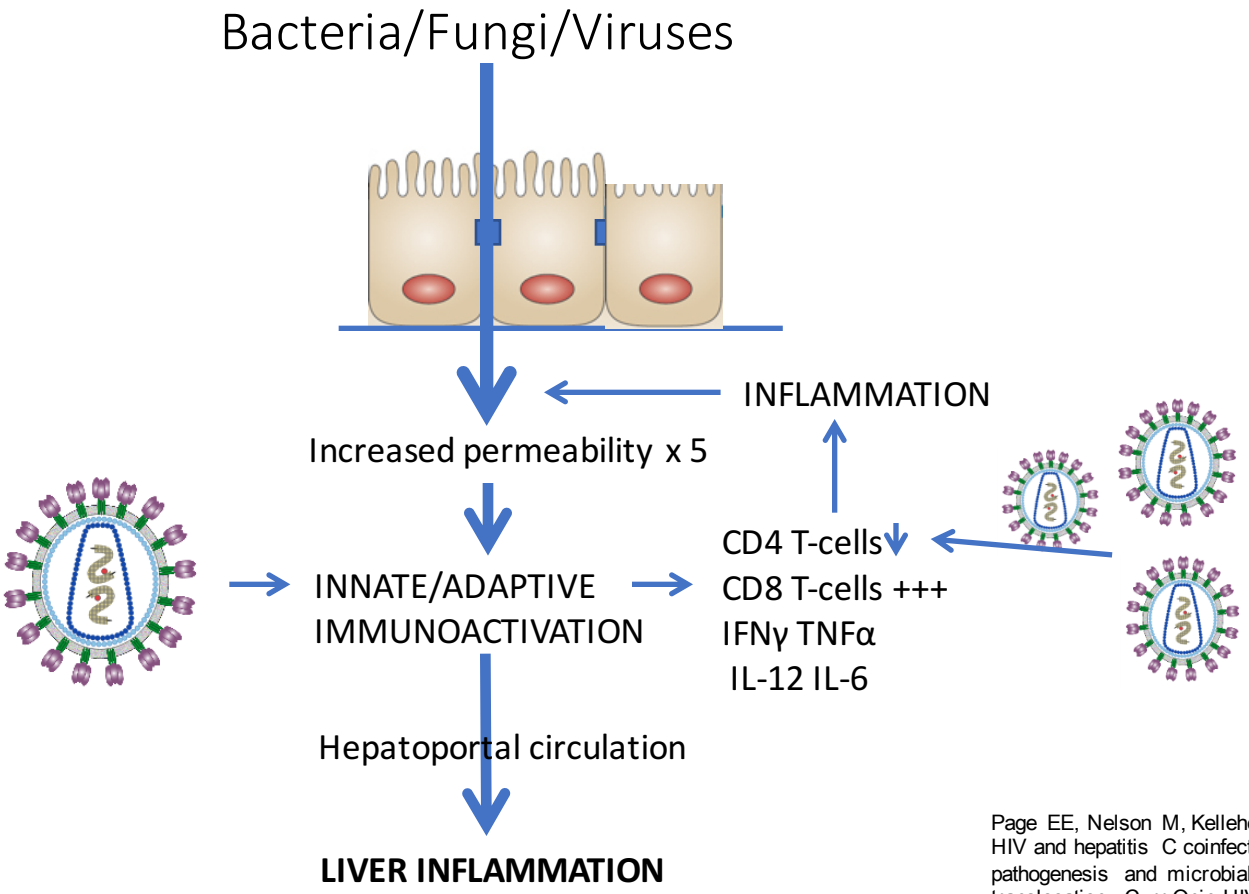

Page EE, Nelson M, Kelleher P. HIV and hepatitis C coinfection: pathogenesis and microbial translocation. Curr Opin HIV AIDS. 2011 Nov;6(6):472-7. Review. PubMed PMID: 21918438.

HIV enteropathy -central to disease progression?

Brenchley JM, Paiardini M, Knox KS, Asher AI, Cervasi B, Asher TE, Scheinberg P, Price DA, Hage CA, Kholi LM, Khoruts A, Frank I, Else J, Schacker T, Silvestri G, Douek DC. Differential Th17 CD4 T-cell depletion in pathogenic and nonpathogenic lentiviral infections. Blood. 2008 Oct 1;112(7):2826-35

- Depletion of TH-17 CD4+ T cells seen in pathogenic lentiviral infections but not non-pathogenic
- TH-17 CD4+ in humans with HIV specific for gut bacteria and fungi

HIV enteropathy -central to disease progression?

Estes JD, Harris LD, Klatt NR, Tabb B, Pittaluga S, Paiardini M, Barclay GR, Smedley J, Pung R, Oliveira KM, Hirsch VM, Silvestri G, Douek DC, Miller CJ, Haase AT, Lifson J, Brenchley JM. Damaged intestinal epithelial integrity linked to microbial translocation in pathogenic simian immunodeficiency virus infections. PLoS Pathog. 2010 Aug 19;6(8

- In rhesus macaques, gut bacterial translocation an early and sustained event
- In sooty mangabeys, there is no evidence of increased permeability or bacterial translocation

HIV enteropathy -central to disease progression?

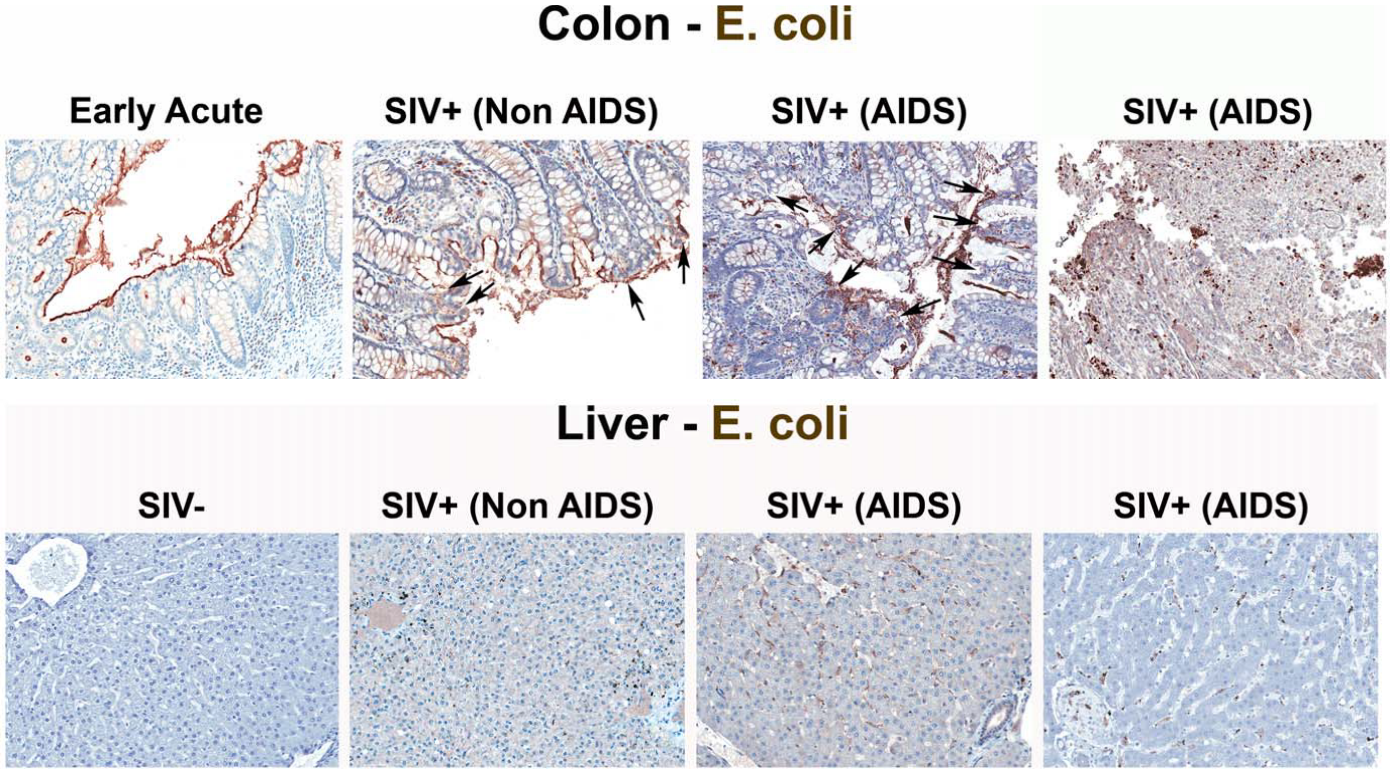

HIV enteropathy -central to disease progression?

E Coli

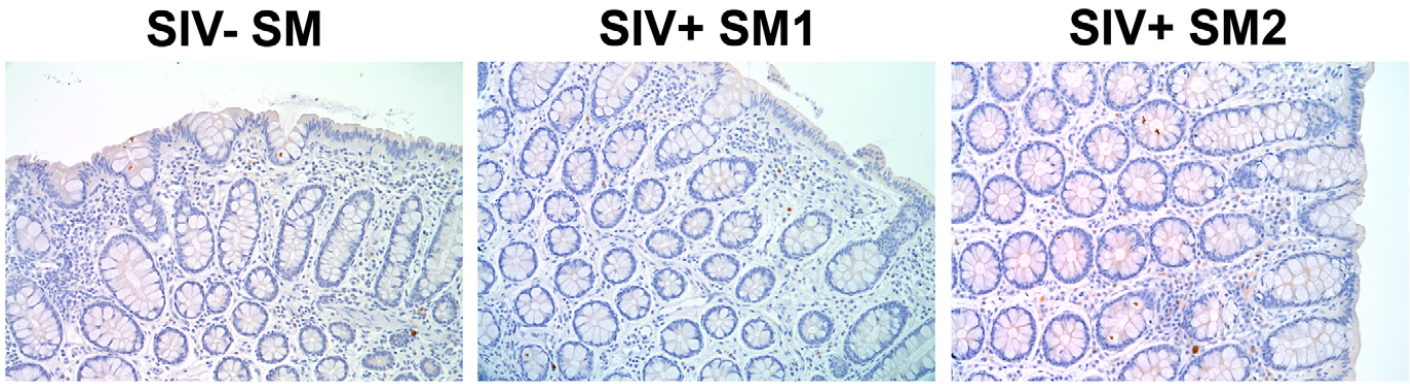

Nodular Regenerative Hyperplasia

- HIV and didanosine associated
- Portal hypertension in the absence of significant fibrosis on biopsy