

2016 IANS International Guidelines for Practice Standards in the Detection of Anal Cancer Precursors

Richard John Hillman, MD, PhD,^{1,2} Tamzin Cuming, MD,³ Teresa Darragh, MD,⁴
 Mayura Nathan, MBBS, FRCP,⁵ Michael Berry-Lawthorn, MD,⁶ Stephen Goldstone, MD,⁷
 Carmella Law, MB, BS, FACHSHM, MBA,⁸ Joel Palefsky, MD,⁹ Luis F. Barroso, MD,¹⁰ Elizabeth A. Stier, MD,¹¹
 Céline Bouchard, MD,¹² Justine Almada, BA,¹³ and Naomi Jay, PhD, RN¹⁴

Objectives: To define minimum standards for provision of services and clinical practice in the investigation of anal cancer precursors.

Methods: After initial face to face meetings of experts at the International Papillomavirus meeting in Lisbon, September 17 to 21, 2015, a first version was drafted and sent to key stakeholders. A complete draft was reviewed by the Board of the International Anal Neoplasia Society (IANS) and uploaded to the IANS Web site for all members to provide comments. The final draft was ratified by the IANS Board on June 22, 2016.

Results: The essential components of a satisfactory high-resolution anoscopy (HRA) were defined. Minimum standards of service provision, basic competencies for clinicians, and standardized descriptors were established. Quality assurance metrics proposed for practitioners included a minimum of 50 HRAs per year and identifying 20 cases or more of anal high-grade squamous intraepithelial lesions (HSILs). Technically unsatisfactory anal cytological samples at first attempt in high-risk populations should occur in less than 5% of cases. Where cytological HSIL has been found, histological HSIL should be identified in $\geq 90\%$ of cases. Duration of HRA should be less than 15 minutes in greater than 90% of cases. Problematic pain or bleeding should be systematically collected and reported by 10% or lesser of patients.

Conclusions: These guidelines propose initial minimum competencies for the clinical practice of HRA, against which professionals can judge themselves and providers can evaluate the effectiveness of training. Once standards have been agreed upon and validated, it may be possible to develop certification methods for individual practitioners and accreditation of sites.

Key Words: anal cancer, precursors, high-grade squamous intraepithelial lesions, anal intraepithelial neoplasia, high-resolution anoscopy, anal cytology, quality assurance, practice standards, diagnostics

(*J Low Genit Tract Dis* 2016;20: 283–291)

¹Dysplasia and Anal Cancer Services, St Vincent's Hospital, Darlinghurst; ²Western Sydney Sexual Health Centre, Western Sydney Local Health District, Parramatta, New South Wales, Australia; ³Homerton University Hospital NHS Foundation Trust, Homerton, London, UK; ⁴Department of Pathology Mt. Zion Medical Center; ⁵Homerton Anal Neoplasia Service (HANS), London, UK; ⁶Anal Neoplasia Clinic, Research, and Education Center, San Francisco, CA; ⁷Laser Surgery Care, New York, NY; ⁸St Vincent's Centre for Applied Medical Research, St Vincent's Hospital, Darlinghurst, New South Wales, Australia; ⁹University of California—San Francisco, San Francisco, CA; ¹⁰Wake Forest Baptist Health Infectious Diseases/Internal Medicine, Winston-Salem, NC; ¹¹Obstetrics and Gynecology, Dysplasia Services, Boston University Medical Center, Boston, MD; ¹²Centre Médical Berger Centre, Chemin Sainte-Foy, Québec, Canada; ¹³Anal Cancer Foundation, Dumbo, Brooklyn, NY; and ¹⁴UCSF ANCRE Center, Mount Zion Hospital, San Francisco, CA

Reprint requests to: Richard John Hillman, MD, PhD, The University of Sydney, Western Sydney Sexual Health Centre, 62 Marsden St, Parramatta, Australia. E-mail: Richard.Hillman@sydney.edu.au

The authors have no financial support to declare.

The authors have declared they have no conflicts of interest.

Review board status: This paper does not contain any research involving people or animals nor human images, so does not include a statement of review board status, consents for research or a statement of patient consent.

© 2016, American Society for Colposcopy and Cervical Pathology

DOI: 10.1097/LGT.0000000000000256

PURPOSE

To define minimum standards for provision of services and clinical practice in the investigation of anal cancer precursors.

Currently, patient assessment for anal cancer precursors consists of the digital anorectal examination (DARE), anal cytology and high-resolution anoscopy (HRA) examination. However, the final arbiter in the detection of an anal cancer precursor is with histological verification of an HRA-directed biopsy sample indicating HSIL. This document focuses on HRA examination and the biopsy procedures that help procure an accurate histological diagnosis of high-grade squamous intraepithelial lesions (HSILs). Treatment of anal cancer precursors is not addressed.

BACKGROUND

Anal squamous cell carcinoma (ASCC) is a stigmatized condition that frequently presents late, with corresponding poor prognosis, and typically requires chemoradiotherapy.¹ Although rare in the general community, it occurs more commonly in specific populations, such as in HIV-infected men who have sex with men (MSM), who have rates more than 80 times higher than HIV-uninfected men.² Women with previous human papillomavirus (HPV)-associated anogenital disease also have higher rates.³ Furthermore, the annual incidence of ASCC is increasing, particularly in these high-risk populations.⁴

There are many epidemiologic, virologic, cytological, and histological similarities between ASCC and cervical cancer, including the presence of the precursor, high-grade squamous intraepithelial lesion. Such similarities have fostered requests for the introduction of screening programs, striving to replicate the public health successes of the cervical cancer/cervical HSIL screening programs. Although estimated progression rates from HSIL to squamous cell carcinoma are lower in the anus compared with the cervix,^{5,6} identifying anal HSIL in an accurate and reproducible manner potentially allows for early diagnosis and interventions aimed at reducing anal cancer rates in high-risk populations.

METHODS

After discussions between experts in the field at the International Papillomavirus meeting in Lisbon, September 17 to 21, 2015, a first version of proposed guidelines for practice standards in the detection of anal cancer precursors was developed. This was sent to key international stakeholders and a complete draft discussed at a Board meeting of the International Anal Neoplasia Society (IANS) in March 2016. A draft was then uploaded to the IANS Web site and an email sent to all IANS members for comments. These comments were included, and following further discussions, the final draft was ratified by the IANS Board at their meeting on June 22, 2016.

What Is HRA and Why Do We Need Standards?

Anal cytology has been used to predict those at risk of HSIL, but the limited sensitivity restricts its usefulness as a potential screening technique.⁷ High-resolution anoscopy with directed biopsy, a technique similar to cervical colposcopy,⁸ is currently the gold standard against which anal cytology and other diagnostic procedures are compared. High-resolution anoscopy developed simultaneously in several countries and has been used to help identify anal HSIL for more than 2 decades.⁹ However, the procedure for HRA is not standardized, and variations in HRA procedural techniques worldwide are not well documented. Most of these clinical HRA services are recent developments, suggesting that the numbers and locations of these services may be continuing to grow. For example, the International Anal Neoplasia Society (<http://ians.memberlodge.org/>) newly created in 2013 has members from at least 21 countries, including the following: Australia, Belgium, Brazil, Canada, Dominican Republic, France, Greece, Indonesia, Italy, Japan, The Netherlands, Philippines, Poland, Portugal, Puerto Rico, Russian Federation, Spain, Switzerland, Thailand, United Kingdom, the United States, and Venezuela. In addition to this geographical spread, there is also a considerable diversity in the professional backgrounds of HRA practitioners, including those from infectious diseases, HIV and sexual health, colorectal surgery, gynecology, family medicine, and dermatology. A survey of colon and rectal surgeons found that less than half who state they perform HRA have ever been formally trained. An analysis of their techniques showed that most did not conform to basic recommendations for HRA established by recognized experts in the

field.¹⁰ Moreover, the procedure itself is not always completely described in publications, making comparison between reports difficult. Finally, a number of ablative and pharmacologic treatments for anal HSIL are currently used, requiring additional training beyond the purview of this guideline. However, it is well recognized that HRA-guided identification of HSIL can be pivotal to successful eradication of HSIL.

The establishment of common standards for HRA would therefore potentially be valuable to the following:

1. ensure minimum competencies for the clinical practice of HRA
2. define minimum acceptable standards for professional continuing clinical practice and contribution to research studies
3. allow more meaningful comparison of research data. This is particularly relevant after the recent development of uniform histological reporting standards for anogenital HPV-associated squamous lesions¹¹
4. assess the value of individual components of training, including the effect of experience, techniques used, equipment, and length of time performing HRA on developing proficiency¹²⁻¹⁵

DEFINITIONS

High-resolution anoscopy is the examination of the anal canal and perianus using a colposcope for lighting and magnification, after application of 5% acetic acid and Lugol iodine solutions to identify anal lesions.

TABLE 1. Quality Assurance Metrics for Selected Specialties and Jurisdictions

Specialty	Jurisdiction	Contents
Colposcopy	United States	None (although mentorship programs exist and colposcopy practice standards are currently under evaluation through the ASCCP)
	United Kingdom BSCCP (2016)	Minimum caseload of 50 cases per year, comprising: <ul style="list-style-type: none"> • ≥25 new cases with abnormal cytology • ≤25 new cases referred with abnormal symptoms or an abnormal appearing cervix or multi focal lower genital tract disease referrals within or between colposcopy clinics • >90% biopsies should be suitable for histological interpretation • predictive value of a colposcopic diagnosis of a high-grade lesion (cervical intraepithelial neoplasia grade 2 or worse) should be at least 65% • Biopsy should be undertaken in >95% of women with high-grade abnormalities
	Australia (ASCCP)	<ul style="list-style-type: none"> • Have completed the Colposcopy Online Learning Program within 12 months before application for certification • Provide evidence of having completed 100 colposcopic examinations, 50 of which must be new cases • Provide evidence of satisfactory completion of the in house clinical assessment 'Colposcopy and the Treatment of Cervical Disease' • Complete a logbook of 10 documented treatments for high-grade lesions of the cervix (therapeutic stream) • Provide a letter of competency signed off by their training supervisor
	Canada (Tinmouth J 2014)	A minimum of: <ul style="list-style-type: none"> • 6 months technical training • 300 completed procedures with at least 50 polypectomies performed to achieve accreditation • 200 colonoscopies per year to maintain privileges, with at least a 95% cecal intubation rate
Gastrointestinal endoscopic procedures	USA (ASGE 2015)	Preprocedure, intraprocedure, and postprocedure indicators with levels of supportive evidence and specified performance targets, separated by process and outcome measures
	United Kingdom (Group 2011)	≥100 procedures/year (150/year "aspirational") Joint Advisory Group on Gastrointestinal Endoscopy: individual—90% cecal intubation rate; 15% polyp detection rate; unit: patient feedback; cleanliness; standards of decontamination

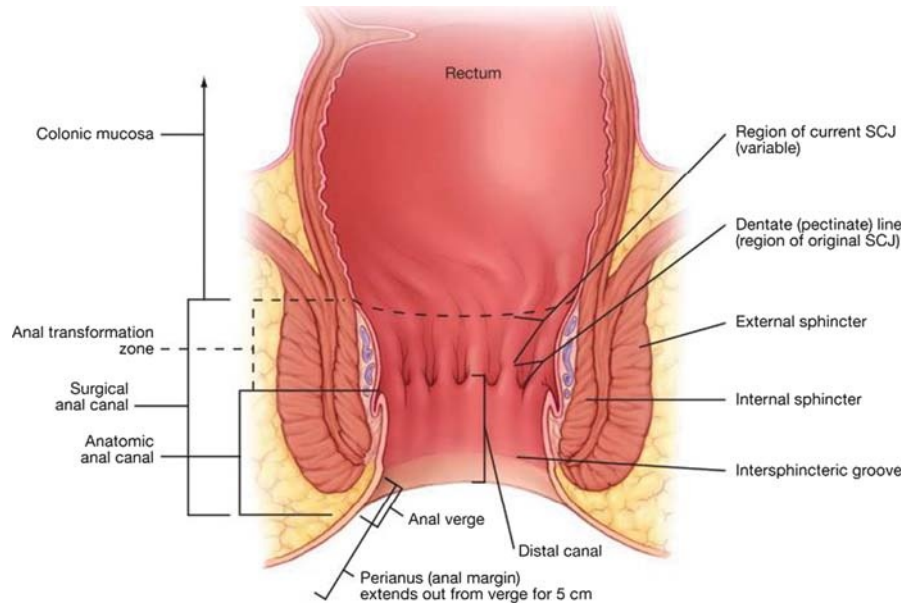


FIGURE 1. Anatomy of the anal canal and perianus. Source: Darragh TM, B. J., Jay N, Palefsky J, Ed. (2011). (Darragh TM 2011).

The squamo-columnar junction (SCJ) is the junction where the squamous anal epithelium abuts the colonic columnar epithelium.

The anal transformation zone (AnTZ) is the zone where all aspects of squamous metaplasia are currently found and have occurred.

A complete and satisfactory HRA is one in which the anus is completely visualized, including the following:

- entire anal canal from the SCJ at the border of the distal rectum
- AnTZ
- distal canal
- anal verge
- perianus

As with cervical colposcopy, HRA relies on the clinician’s ability to recognize abnormalities in the acetic acid and Lugol staining patterns of the epithelium, changes in vessel patterns, and morphologic features such as friability, ulceration and mass effect. In this manner, it is possible to identify and distinguish the presence of potential HSIL and early, non-palpable cancers, from other benign findings.

Details of how to perform an examination are available elsewhere.¹⁶ As a minimum, this requires a good quality colposcope

with adequate lighting and magnification, together with an examination table and provider seat, that allow for reasonable examination ergonomics and comfortable positions for both examiner and patient.

High-resolution anoscopy can be a technically and physically challenging examination. Specific features include the following:

- a) the clinician must hold the anoscope in position throughout the examination, adjusting where necessary, to fully visualize the entire AnTZ, including the SCJ, while refocusing and repositioning the colposcope as needed;
- b) the large surface area of the AnTZ, anal canal, and perianus, together with anatomical obstacles, such as mucosal folds and papillae, can be challenging to fully visualize;
- c) microscopic features helping to identify anal HSIL may be subtle, requiring higher magnification compared with the cervix⁸;
- d) widespread, multifocal disease is often present;
- e) coexisting pathology may be present, such as condyloma, hemorrhoids, anal fissure, and fistula in ano;
- f) changes may be present from treatment-related scar tissue, strictures, and irradiation changes from previous radiotherapy—potentially adding complexity to the interpretation of patterns seen;

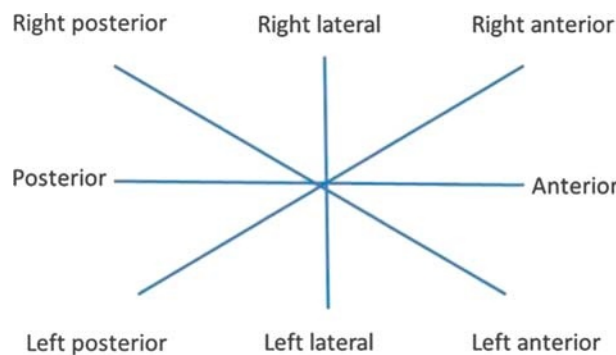


FIGURE 2. Location descriptors (for patient in the left lateral position). Note: The location of these descriptors are markedly different if the patient is in a prone or lithotomy position.

TABLE 2. General High-Resolution Anoscopy Descriptors

Section	Pattern
General assessment	Adequate or inadequate for the reason (eg, SCJ obscured by hemorrhoids, mucosal folds, inflammation, bleeding, scar) Squamocolumnar junction visibility: completely visible, partially visible, not visible or percentage of SCJ viewed.
Normal HRA findings	Original squamous epithelium Columnar epithelium
Abnormal HRA findings	Metaplastic squamous epithelium; gland openings Location of the lesion at or near SCJ, or off SCJ Location of the lesion by anterior/posterior/left/right position and proximal to distal location Size of the lesion: number of octants the lesion covers Size of the lesion as percentage of anal canal, such as extent from, for example, dentate line to SCJ or to distal canal Color: white, gray-white, red
Suspicious for invasion	Lesion descriptors (such as contour, surface patterns, vascularity, margins, Lugol staining, as detailed in Table 3) Metaplastic changes indicative of lesions may include atypical metaplastic qualities such as lacy borders, clustered gland openings, and epithelial honeycombing Nonspecific: leukoplakia (keratosis, hyperkeratosis), erosion, ulcer Atypical vessels Additional signs: friability, irregular surface, exophytic lesion, necrosis, ulceration, (necrotic), tumor or gross neoplasm
Miscellaneous findings	Condyloma, physiological papillae, rectal polyp (inflammation, stenosis, congenital anomaly, posttreatment consequences)

SCJ indicates squamocolumnar junction.
(Adapted from Bornstein J et al [Bornstein J, 2012]).

g) the psychosocial and emotional state of the patient being examined may either facilitate or make the exam even more challenging.

Most published data are from studies in MSM, particularly those who are HIV positive. However, in the general population, women develop anal cancer more commonly than men, and rates

TABLE 3. Description of Lesion Characteristics

Category	Characteristic	Description
Contour	Flat	No elevation or minimal thickening, may be irregular or uneven
	Raised	Exophytic, verrucous, thickened, often in association with papillary changes
Surface patterns	Smooth	Even, without texture
	Granular	Irregular, coarse, or gritty
	Papillae Micropapillae	Thin, finger-like projections, often with warty looped vessels Slightly raised projections, similar to papillae but flattened in comparison, small capillary vessels may be present
Vascularity	Punctation	End-on view of dilated capillary vessels creating dotted pattern, which maybe fine or coarse
	Mosaic pattern	Tile-like pattern of connected vessels, even or uneven, fine or coarse and thickened
Margins	Warty vessels	Looped capillary vessels often within papillae or verrucous lesions
	Distinct	Well-demarcated borders, sharply defined, may have internal margins
	Regular	Symmetrical, straight, or smooth outline
Lugol stain	Indistinct	Feathery, borders lacking clarity
	Negative	No iodine uptake, yellow
	Partial Complete	Variable iodine uptake, speckled appearance of yellow and brown Mahogany brown coloring, uniform uptake

(Adapted from Jay [Jay N, 2015]).

TABLE 4. Recommended Practical Competencies

Conduct a consultation before the HRA procedure where there is an adequate explanation to patient of what to expect, as well as covering initial queries
Adhere to local infection control procedures
Obtain either verbal or written informed consent
Take a technically adequate anal cytological sample
Perform a digital anorectal examination
Insert a lubricated anoscope without causing the patient undue discomfort
Operate a colonoscope
Repeatedly apply 5% acetic acid
Apply Lugol iodine
Examine the SCJ at the border of the distal rectum, the anal transformation zone, the distal canal, through to the anal verge and perianus
Identify, anatomically locate, and describe any morphologic variants
Identify, anatomically locate, and describe any abnormalities
Develop an impression of the key clinical problems and differential diagnosis
Perform adequate anal canal and perianal biopsies
Achieve hemostasis
Communicate the anoscopy examination findings and the pathway for future care to patient and other care providers
Refer onward appropriately

HRA indicates high-resolution anoscopy; SCJ, squamocolumnar junction.

of anal cancer and HSIL are also elevated in other immunosuppressed populations groups.^{17–19} It is currently unknown whether optimum HRA practices or specific findings differ between these groups, and the only way that this can be investigated is to compare clinical findings from HRA tests that have been carried out to set quality standards.

What Comparable Specialties Do

Both colonoscopy and endoscopy have established and validated quality standards, complemented by robust training and ongoing quality criteria for individuals and for clinical service units that are subject to inspection^{20–23} (Table 1). Ensuring a standard of performance is a valuable quality assurance measure for inclusion in screening programs aiming to prevent cancer. It is therefore appropriate that, before such a program can be introduced to prevent anal and other lower anogenital tract cancers, similar stringent standards need to be validated and implemented.

Proposed Minimum Standards for HRA Services

In the absence of data indicating optimum practice, the International Anal Neoplasia Society has developed guidance among current HRA practitioners. Although this may vary somewhat according to the size of the clinic population, referral pattern, case mix, level of expertise, training commitments, and research activities, the key components should include the following:

Set Up of HRA Services

- The room for conducting examinations must permit adequate privacy, confidentiality and dignity, and have nearby toilet facilities.
- The position of the patient during the procedure can be left (or right)-lateral, prone or lithotomy. Whichever is used, the patient's comfort during examination should be ensured.

- Adequate resuscitation facilities for local anesthetic overdose, vasovagal reactions and for allergic reactions should be readily available and staffed trained in their administration. Adequate equipment and training of staff in procedures to stop excessive bleeding should be available.
- Patient information should be given, detailing the procedure, ideally before the examination. The information should outline the purposes of the examination, any preparation necessary, likely pain and bleeding that may be involved, as well as the potential benefits.
- Informed consent, as required by local regulations and customary practice, should be obtained at all times. Depending on local practices, this may be verbal consent. However, consideration should be given to using a written consent process, perhaps in conjunction with a preprocedural information leaflet.
- Staffing levels should be adequate. In addition to the HRA practitioner, a health-care professional (such as a trained nurse or medical assistant) is desirable. If another staff member is present during the HRA, they should undergo appropriate training re language and behavior during the procedure.
- Cleaning of the room between cases must comply with local infection control policies. Although HRA is not a sterile procedure, avoidance of cross-contamination is important. This is best carried out in consultation with the Infection Control department of your institution.
- Sterilization of biopsy forceps should similarly be discussed with Infection Control.
- HRA findings should be accurately recorded in the medical notes and include anatomical location and a detailed description of lesions, using accepted descriptors. Annotated digital photography may be considered to supplement drawings
- Clear policies must be in place to ensure accurate reporting of examinations, follow-up arrangements, communication of results, and the expediting of care for urgent or cancer cases. It is highly recommended to provide each patient with concise information on what to do post-HRA and ways of contacting the nurse/physician or institution in case of adverse events.
- Follow-up information should be solicited from patients, regarding their experiences during and after the procedures. If this cannot be done as a routine, it would be beneficial for the service to obtain feedback at least annually.
- A close working relationship with surgical colleagues is required for the prompt management of complications and

TABLE 5. High-Resolution Anoscopy Adequacy Criteria

Informed consent obtained as per protocols
The entire anal transformation zone visualized
5% acetic acid repeatedly applied to the AnTZ, anal canal, and perianus
Lugol solution applied adjunctively
Biopsies taken from areas suspicious for HSIL (that have not been previously documented)*
Adequate documentation of the whole examination has occurred

AnTZ indicates anal transformation zone; HSIL, high-grade squamous intraepithelial lesions.

Notes: Some practitioners also include staining with Lugol iodine as part of the intra-anal examination, to assist with the identification and characterization of HSIL.

*If no changes suggestive of high-grade squamous intraepithelial lesions have been identified at HRA, in some circumstances, consideration may be given to performing random biopsies, with attention to the AnTZ.

TABLE 6. Volume of Practice Criteria

Code	Metric	Minimum cases	Recommended
A.1	Anal cytology samples taken per year	50	≥100
A.2	HRAs completely performed per year	50	≥100
A.3	Histological HSIL diagnoses per year	20	≥50

HSIL indicates high-grade squamous intraepithelial lesions.

Note: It is understood that some practice settings may not have populations considered at high risk for anal high-grade squamous intraepithelial lesions and, therefore, may have a lower volume of examinations.

complex or advanced cases. After consultation with the colleagues, there should be clear policies guiding processes for both internal and external referrals.

- Those units managing anal cancer should have access to health-care providers with specialized knowledge and be able to advise patients and their relatives.
- Diagnosis and treatment of anal HSIL and ASCC requires the input of clinicians from multiple specialties. It is important to have a team approach, with clinicians working closely for the benefit of good patient care. Specialties potentially involved include medical oncologists, colorectal surgeons, HIV/sexual health physicians, radiation oncologists, and histopathologists/cytopathologists.

Anatomical Terms

Standard anatomical location reporting is crucial to orient any subsequent care or reexamination by different providers. Figure 1 illustrates that the anus is divided into the anal canal and perianus. The anal canal is divided into distal/proximal regions:

- distal rectum
- squamocolumnar junction
- dentate line
- mid-canal
- distal canal
- anal verge

The perianum extends 5 cm laterally from the anal verge (margin) and is visualized by gentle retraction of the buttocks.

Location Descriptors

The location descriptors used must be independent of the position of the patient, with the use of “o’clock” terminology

avoided wherever possible. This is because of the marked differences in meaning, depending on whether the patient is in a left lateral, prone, or lithotomy position.

The canal into can be divided into octants, circumferentially, as illustrated in Figure 2.

Lesion location can additionally be recorded in the anal canal with respect to its proximal/distal extent as at/near the SCJ, mid-canal, distal canal, and perianus. This allows the anal canal to be described by smaller sections, which may assist in the assessing of the extent of disease. Consideration should be given documenting the anatomical area of HSIL (both intra-anal and perianal lesions), in the form of photographs and/or diagrams to further provide a record of volume of disease as this may be important in monitoring progress and may be a marker for disease progression.

General HRA Descriptors

After direct, repeated, and comprehensive application of 5% acetic acid to the entire anal canal (+/- Lugol iodine for the intra-anal canal), the details in Table 2 should be recorded.

Lesion Descriptors

It is recommended that lesions are seen using the terminologies listed in Table 3.

Training

Depending on their jurisdiction, colposcopists may need to initially satisfy a number of training requirements, including E-learning, attendance at courses, preceptorships, mentorships, and completion of practice log books. Until further data are available, training in HRA practice could ideally include a number of components:

- attendance at a basic HRA course, organized by a recognized professional society;
- knowledge of anorectal anatomy and physiology, epidemiologic characteristics of HPV-associated anal disease, cyto/

TABLE 7. Technically Unsatisfactory Anal Cytological Sampling Rates

Code	Metric	Recommendation
B.1	Technically unsatisfactory anal cytological sample (at first attempt) - in highest risk populations: for example, HIV-positive MSM	<5%*
B.2	Technically unsatisfactory anal cytological sample (at first attempt) - in lower risk population: for example, HIV-negative women	<15%

HIV indicates human immunodeficiency virus; MSM, men who have sex with men.

Note: The figure may be higher than 5% in populations where the prevalence of HPV-associated abnormalities is low. The presence of one abnormal cell in a sample technically makes the sample “adequate,” even if it is very scant.

TABLE 8. High-Resolution Anoscopy Performance Metrics

Code	Metric	Recommendation
C.1	Entire SCJ, AnTZ, distal anal canal and perianus fully visualized	>90%
C.2	Average number of biopsies performed per procedure for new patients ¹	>1
C.3	Detection of histological HSIL within 3 months after initial cytological HSIL	>90%
C.4	% perianal biopsies ²	≥5%

SCJ indicates squamocolumnar junction; AnTZ, anal transformation zone; HSIL, high-grade squamous intraepithelial lesions.

Notes:

¹Will depend on mix of patients, such as referral practices, new or return, high risk and treatment experience.

²Depending on % of anal cancers that are perianal in local population.

- histopathologic terminology, and clinical features of anal HPV-associated disease, together with their diagnosis and management;
- iii. observation of an experienced HRA practitioner;
 - iv. preceptorship—a formal program of visits by expert to observe practice as part of a specifically designed training program;
 - v. mentorship—discussing cases with identified experts, focused on the acquisition of practical clinical competencies;
 - vi. multidisciplinary discussions with cytologists, pathologists and clinicians, to improve clinicopathologic correlations and refine lesion identification; and
 - vii. regular patient feed-back of the service and care.

Continuous learning and review of performance are an integral part of developing and maintaining practice techniques.

Once a defined training syllabus and assessment metrics have been developed and evaluated, further work will be required to identify which aspects of training yield the highest quality outcomes.

TABLE 9. Patient Experience Metrics

Code	Metric	Recommendation
D.1	Duration of HRAs ¹	90% <15 minutes >90% lasting ≥5 min
D.2	Problematic pain ²	≤10%
D.3	Problematic bleeding ³	≤10%

HRA indicates high-resolution anoscopy.

Notes:

¹Defined from insertion of anoscope (after initial application of 5% acetic acid) to the final removal of the anoscope. Although longer insertion times may be associated with greater likelihood of finding high-grade squamous intraepithelial lesions, they result in increasingly adverse patient experiences. Duration may be longer in new patients compared with those previously seen.

²Defined by patient as “a lot” or “severe” (“none” or “some” not regarded as significant). Consideration could be given to the use of a 0 to 10 visual analogue scale, where ≥7 could be regarded as problematic.

³Defined by patient as a duration ≥1 week, with spotting of underwear or bed clothes, or clots ≥1 cm.

^{2,3}Solicited from patients within 2 weeks of procedure. Ideally, this should be obtained in a systematic fashion, at least once per year from a select group of patients.

Practical Competencies

Before commencing independent clinical practice of HRA, clinicians should be able to perform all of the competencies listed in Table 4.

Definition of an Adequate HRA Examination

A HRA can only be considered to have been adequately performed if the all the components in Table 5 have been achieved.

Quality Assurance Metrics

The aims of quality assurance (QA) metrics are as follows:

- a) to maximize the likelihood of the accurate detection of the presence and extent of HSIL and early cancers, and
- b) to capture patient experience to minimize discomfort.

Good QA standards aim to achieve high levels of correlation between cytology, HRA descriptions, and histological diagnoses. This may be especially relevant when a patient is referred with previously established cytological or histological evidence of HSIL.

To support the measurement of quality indicators, the terms *auditable outcome* (an important indicator, based on expert opinion, for which no clear evidence base exists) and *quality standard* (an auditable outcome for which there is an evidence base that can support a minimum standard) have been identified for colonoscopy.²⁴ With respect to the individual components of performing HRA, no clear evidence currently exists to support the setting of clinical practice standards. Nevertheless, there are key performance indicators that are based on a consensus of expert opinion and could potentially be monitored in the future, to obtain that evidence.

These metrics are proposed as a means of establishing initial benchmarks, against which data can be collected in a prospective fashion and the metrics modified in response to experience. These are suggested minimum standards. Individual units may choose to set higher standards.

It is likely that the ability to achieve these metrics will vary with the population being examined. For example, a true screening population will have lower rates of HSIL, whereas a group already identified for treatment is likely to have higher rates. Although the prevalence of HSIL clearly differs between various risk groups, clinical experience does not currently suggest that there is likely to be any significant variation in the performance of HRA and appearance of lesions.

TABLE 10. Possible Additional Metrics

Code	Metric	Recommendation
E.1	Inadequate biopsy rates (including pathologist unable to comment on grade of squamous intraepithelial lesion because of lack of depth, colonic biopsies, and no tissue)	<10%
E.2	If cHSIL identified, but no hHSIL detected, then patient to be recalled within 6 months for repeat HRA	>90%

cHSIL indicates cytological evidence of high-grade squamous intraepithelial lesions; hHSIL, histological evidence of high-grade squamous intraepithelial lesions; HRA, high-resolution anoscopy.

Note: These figures may be influenced by factors such as:

- i) Percentage of patients in which HSIL found.
- ii) Correlation between extent/number of HSIL lesions identified by diagnosing anoscopist and at the treatment examination (if the latter is more experienced in HRA).

Volume of Practice

The time taken to become proficient is inversely proportional to the volume of practice^{12,15} and ideally would involve a minimum of 5 HRAs examinations per week. Volume of practice criteria are given in Table 6.

Anal Cytological Sampling

Recommended proportions of technically unsatisfactory anal cytological sampling rates are given in Table 7.

HRA Metrics

High-resolution anoscopy performance metrics are based on the assumption that cytological changes of HSIL (cHSIL) strongly suggest that histologically verifiable HSIL (hHSIL) is present. There may be rare exceptions, such as profound immunosuppression, post radiotherapy, and very early on in the development of HSIL lesions when these associations differ. These metrics are currently based on expert opinion but will be reviewed as evidence is generated. Table 8 lists the recommended metrics.

Patient Experience (for diagnostic HRA only)

Ensuring minimal levels of discomfort for patients undergoing procedures is a key component of high-quality services and helps with maintaining follow-up. Recommended metrics are given in Table 9.

Possible Additional Metrics

Depending on the clinical or research contexts and availability of resources, consideration may be given to the additional metrics listed in Table 10.

Practice Logbook

The completion of a deidentified log book in an ongoing fashion is strongly recommended. This facilitates reflective learning, allows the collection of the above metrics, and can be audited, if required.

An example of a logbook is given in Figure 3.

CONCLUSIONS

Rising rates of anal cancer, greater understanding of the natural history of HSIL, the precursors to anal cancer, and increasing abilities to intervene, have meant growing interest in the provision of related diagnostic and therapeutic procedures. These opinions and guidelines are currently delivered by a diverse group of professionals from varying backgrounds. We await the outcomes a number of large clinical trials (eg, ANCHOR [https://clinicaltrials.gov/ct2/show/NCT02135419], SPANC,²⁵ LOPAC http://www.hra.nhs.uk/news/research-summaries/lopac-laser-ablation-versus-observation-to-prevent-anal-cancer-v-1-0/ etc.) to provide the evidence base for optimum screening and management of hHSIL. However, an increasing number of clinical services are being introduced in response to the pressing clinical need to identify and closely monitor those at very high risk of anal cancer.

Competent practitioners should be able to find most histological HSIL present, most of the time. Agreed criteria for what constitutes adequate HRA examination and acceptable levels of clinical service will greatly facilitate the interpretation of clinical and research data, together with the development of multicenter, multinational trials designed to address this growing clinical problem.

This guideline proposes initial minimum competencies for the clinical practice of HRA, against which professionals can judge themselves and providers can evaluate the effectiveness of training. Once standards have been agreed upon and validated, it

FU or New	Date of HRA + Unit Number	Recent cytology result + date taken	Anoscopic Impression (include % SCJ seen)	Intra-anal abnormalities + sites of biopsies	Perianal abnormalities + sites of biopsies	Histology (with locations)

FIGURE 3. Quality assurance logbook. FU indicates follow up; HRA, high resolution anoscopy; SCJ, squamocolumnar junction; IA, intraanal; PA, perianal; RL, right lateral; RA, right anterior; A, anterior; LA, left anterior; LL, left lateral; LP, left posterior; P, posterior; RP, right posterior.

may be possible to develop certification methods for individual practitioners and accreditation of sites.

ACKNOWLEDGMENTS

The authors thank all IANS members for the valuable feedback.

REFERENCES

- Glynn-Jones R, Renehan A. Current treatment of anal squamous cell carcinoma. *Hematol Oncol Clin N Am* 2012;26:1315–50.
- Silverberg MJ, Lau B, Justice AC, et al. Risk of anal cancer in HIV-infected and HIV-uninfected individuals in North America. *Clin Infect Dis* 2012;54:1026–34.
- Edgren G, Sparén P. Risk of anogenital cancer after diagnosis of cervical intraepithelial neoplasia: a prospective population-based study. *Lancet Oncol* 2007;8:311–6.
- Grulich AE, Poynten IM, Machalek DA, et al. The epidemiology of anal cancer. *Sex Health* 2012;9:504–8.
- Darragh TM, Winkler B. Anal cancer and cervical cancer screening: key differences. *Cancer Cytopathol* 2011;119:5–19.
- Machalek DA, Poynten M, Jin F, et al. Anal human papillomavirus infection and associated neoplastic lesions in men who have sex with men: a systematic review and meta-analysis. *Lancet Oncol* 2012;13:487–500.
- Roberts JM, Thurloe JK. Comparison of the performance of anal cytology and cervical cytology as screening tests. *Sex Health* 2012;9:568–73.
- Jay N, Berry JM, Miaskowski C, et al. Colposcopic characteristics and Lugol's staining differentiate anal high-grade and low-grade squamous intraepithelial lesions during high resolution anoscopy. *Papillomavirus Res* 2015;1:101–8.
- Patel J, Salit IE, Berry MJ, et al. Environmental scan of anal cancer screening practices: worldwide survey results. *Cancer Med* 2014;3:1052–61.
- Factor SH, Cooperstein A, Pereira GA, et al. Are colon and rectal surgeons ready to screen for anal dysplasia? Results of a survey on attitudes and practice. *Sex Transm Dis* 2014;41:246–53.
- Darragh TM, Colgan TJ, Cox JT, et al. The Lower Anogenital Squamous Terminology Standardization Project for HPV-Associated Lesions: background and consensus recommendations from the College of American Pathologists and the American Society for Colposcopy and Cervical Pathology.[Erratum appears in Arch Pathol Lab Med. 2013 Jun; 137(6):738]. *Arch Pathol Lab Med* 2012;136:1266–97.
- Mathews C, Caperna J, Cachay ER, et al. Early impact and performance characteristics of an established anal dysplasia screening program: program evaluation considerations. *Open AIDS J* 2007;1:11–20.
- Swedish KA, Lee EQ, Goldstone SE. The changing picture of high-grade anal intraepithelial neoplasia in men who have sex with men: the effects of 10 years of experience performing high-resolution anoscopy. *Dis Colon Rectum* 2011;54:1003–7.
- Richel O, Prins JM, de Vries HJ. Screening for anal cancer precursors: what is the learning curve for high-resolution anoscopy? *AIDS* 2014;28:1376–7.
- Hillman RJ, Gunathilake MPW, Jin F, et al. Ability to detect high-grade squamous anal intraepithelial lesions at high resolution anoscopy improves over time. *Sex Health* 2016;13:177–81.
- Darragh TMBJ, Jay N, Palefsky J. *The Anal Canal and Perianus: HPV-Related Disease*. American Society for Colposcopy and Cervical Pathology (Author), E. J. Mayeaux Jr. (Editor), J. Thomas Cox MD (Editor) 2011. Modern Colposcopy Textbook and Atlas; Third Edition.
- Stier EA, Sebring MC, Mendez AE, et al. Prevalence of anal human papillomavirus infection and anal HPV-related disorders in women: a systematic review. *Am J Obstet Gynecol* 2015;213:278–309.
- Moscicki AB, Darragh TM, Berry-Lawhorn JM, et al. Screening for anal cancer in women. *J Low Genit Tract Dis* 2015;19(3 Suppl 1):S27–42.
- Gaisa M, Sigel K, Hand J, et al. High rates of anal dysplasia in HIV-infected men who have sex with men, women, and heterosexual men. *AIDS* 2014;28:215–22.
- BSCCP. Colposcopy Training. 2016. Available at: <https://www.bsccp.org.uk/healthcare-professionals/colposcopy-training/>. Accessed April 1, 2016.
- BSCG. Quality and safety indicators for endoscopy. 2016. Available at: http://www.bsg.org.uk/pdf_word_docs/bsg_grs_indic.pdf. Accessed April 1, 2016.
- England PH. Bowel cancer screening: commission, provide, inform. *NHS Bowel Cancer Screening (BCSP) Programme and Population Screening Programmes 2016*. Available at: <https://www.gov.uk/government/collections/bowel-cancer-screening-commission-provide-inform>. Accessed April 1, 2016.
- Rembacken B, Hassan C, Riemann JF, et al. Quality in screening colonoscopy: position statement of the European Society of Gastrointestinal Endoscopy (ESGE). *Endoscopy* 2012;44:957–68.
- Bourikas LA, Tsiamoulos ZP, Haycock A, et al. How we can measure quality in colonoscopy? *World J Gastrointest Endosc* 2013;5:468–75.
- Machalek DA, Grulich AE, Hillman RJ, et al. The Study of the Prevention of Anal Cancer (SPANC): design and methods of a three-year prospective cohort study. *BMC Public Health* 2013;13:946.